DOI: 10.7860/JCDR/2021/48315.14843

Case Report

Dentistry Section

The Use of Computer Guided Tall and Tilted Pin Hole Immediately Loaded Implants (TTPHIL) Technique for Severe Atrophic Maxilla Rehabilitation: A One Year Follow-Up

VENKATA RATNA NAG PUPPALA[1], SARIKA PUPPALA[2], SMITHA DANIEL[3]

(cc) BY-NC-ND

ABSTRACT

For successful placement of dental implants, the clinician needs adequate bone in three dimensions around endo-osseous implants to enhance Bone Implant Contact (BIC) area and primary stability. The absence of optimum bone calls for complex procedures such as sinus lifts, bone augmentations using grafts that aggravates patient morbidity, dramatically higher costs and limited patient satisfaction. To overcome disadvantages of grafting, graft-less solution used in combination or alone, such as tilted implants, use of long, narrow implants, bi-cortical implants, all-on-4 techniques have enhanced patient acceptance and clinical ease. All-on-4 protocol is one such combination treatment concept whose success has been demonstrated mainly in ideal/moderate osseous structures. Further, it accommodates 10-12 teeth per arch, mostly without second molars compromising chewing efficiency and creating cantilevers especially in rehabilitations opposing complete set of natural teeth. Additionally, optimal number of implants required to support full arch prosthesis remains unclear. Therefore, to circumvent the limitations of all-on-4 technique, 6 long (16-25 mm) and tilted implants have been used to restore 14 teeth in severely atrophic maxillary arch of a healthy 75-year-old female in the following case report. Tall implants engage basal cortical bone aiding in immediate fixation and increase in surface area of osseo-integration. All implants were placed using minimally invasive flapless technique and immediately loaded within 3 days with a screw-retained multiunit DMLS prosthesis. The pterygoid cortex engagement of distal implants does not have any deleterious biomechanical effect eliminating the distal cantilever.

Keywords: Bicortical, Cantilevers, Corticalisation, One-stage surgery, Osseodensification, Subcrestal, Surgical template

CASE REPORT

A healthy 75-year-old femal reported to a private clinic with chief-complaint of chewing difficulty. The patient reported history of extraction of three teeth due to mobility one month ago. She did not have any significant medical history or habits. On oral examination, #13,16,21 healing extraction sockets and #14,15,23,24 severely attrited terminal dentition was present. All mandibular teeth were present [Table/Fig-1a] Patient was subjected to panoramic radiograph (GenorayPapaya, Delhi, India) [Table/Fig-1b] and cone-beam computerised tomography scan (Carestream, India) that demonstrated an atrophic posterior maxillary ridge (bone height 6.0 mm, width 4.0 mm), [Table/Fig-2a] Anterior maxilla exhibited reduced bone volume with labial undercuts and irregular crests [Table/Fig-2b]. Bone quality assessed was type 3 in posterior maxilla and posterior part of premaxilla and type 2 in anterior part of premaxilla.

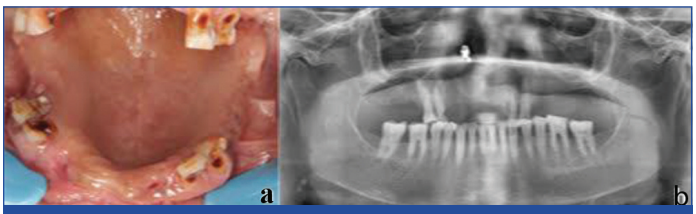

[Table/Fig-1]: a) Pre-operative maxillary picture showing terminal dentition; b) Pre-operative OPG.

Patient was explained in detail about treatment options like implant/tooth supported removable and implant supported fixed prostheses. Patient opted for implant supported fixed prosthesis. Considering the age of patient, it was important to provide patient centric minimally invasive treatment with immediate function. All treatments encompassing morbid sinus grafting and bone augmentations that delayed function were ruled out. Owing to poor bone density and volume in posterior maxilla, higher functional forces in molar region and presence of all mandibular teeth, it was prudent to have longer tilted implants that engage basal cortical bone for purposes of primary stability and immediate function and provide more chewing surfaces in occlusion without any cantilever. All the above factors were considered and Tall and Tilted Pin Hole Placement Immediate Loading (TTPHIL) protocol was recommended [1,2]. After obtaining signed consent for treatment, oral prophylaxis was performed followed by maxillary and mandibular diagnostic alginate (Algitex, DPI, Karnataka, India) impressions. CBCT data was used to make stereolithographic models and surgical stents [Table/Fig-2c].

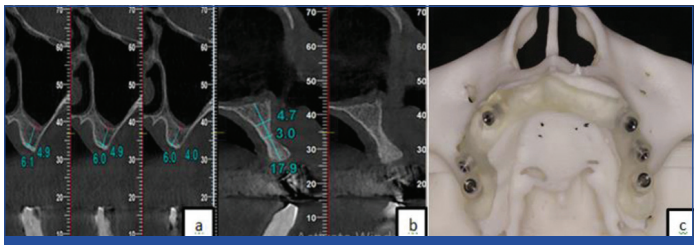

[Table/Fig-2]: a) Maxillary ridge dimensions at #24,25,26; b) Maxillary labial undercuts at #11,12. c) Stereolithographic maxillary model of patient with surgical stent.

One hour prior to surgery, amoxicillin 1 g was given orally and was followed-up with 500 mg for 3 times/daily for next 3 days. All implants (Bioline I, Bioline Dental GmbH&Co.KG, Berlin, Germany) were placed under 2% lignocaine hydrochloride with adrenaline 1:200000 (Lignox 2%). Atraumatic extraction of #14, #15,#23,#24 were done followed by immediate implantation

in same appointment. Surgical template with metal sleeves was placed against alveolar ridge tissue anchored at midline [Table/Fig-3a]. Anterior fixture was placed anterior to anterior wall of maxillary sinus from distal to mesial direction towards nasal cortex in first quadrant. Using surgical guide, a pilot drill of 1.2 mm was positioned through mucosa into alveolar bone upto 6 mm depth [Table/Fig-3b]. Radiovisiographic Image (RVG) (Carestream, Kodak, India) was taken to confirm 30^0 tilt to occlusal plane [Table/Fig-3c].

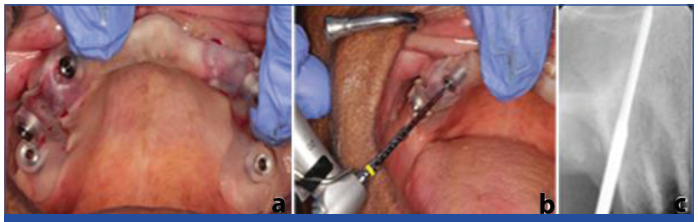

[Table/Fig-3]: a) Surgical STL stent; b) anterior implant 300 drill direction; c) IOPA showing pilot drill direction.

Then, 1.4 mm diameter single drill was used to drill through template at low speed of 400-600 rpm for proprioception of nasal cortex engagement. A 3.5×18 mm tapered implant mounted on implant driver was driven into drilled course. A 40Ncm torque and reverse torqueing forces were obtained using torque rachet. A confirmative RVG was taken. The second implant (3.5×18 mm) was placed using same protocol at premolar site parallel to first implant in distal to mesial direction at 45^0 to occlusal plane. All implants were placed subcrestally. Following palpation of hamular notch, pterygoid implant (3.5×20 mm) drill was directed mesio-distally and bucco-palatally about 5mm laterally at approximately 45^0 to occlusal plane. The drill was stopped after engaging pterygoid cortex [Table/Fig-4a]. A verification RVG with depth guage was taken; implant (3.5×18 mm) was driven slowly until subcrestal placement was achieved. Same approach was followed for second quadrant. 30^0,45^0,45^0 multiunit abutments were placed in anterio-posterior sequence to achieve implant parallelism [Table/Fig-4b].

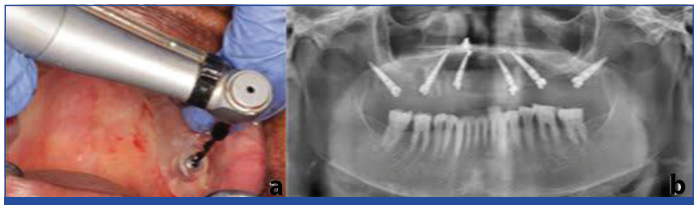

[Table/Fig-4]: a) Pterygoid implant 45° drill direction; b) OPG showing 6 tilted implants with multiunit abutments.

Provisional fixed prosthesis was delivered until permanent prosthesis was fixed. Impression copings (Bioline-I, Bioline Dental GmbH & Co.KG, Berlin, Germany) with appropriate diameters were placed on multiunit abutments and splinted with pattern-resin (GC pattern resin, GC dental, India) to transfer intraoral spatial relationship of nonparallel implants to working cast accurately and achieve prosthesis passive fit [Table/Fig-5a]. Implant level impressions using the open tray technique were made [Table/Fig-5b].

Two stage impression techniques using putty and light body (GC Flexseed, GC dental, India) was followed. Titanium based metal cylinders (Ti-bases) were screwed onto multiunit abutments and customised to interocclusal height. Aluwax (Maarc perfect bite, Hyvincare, India) was engaged around metal bases and interocclusal bite recorded [Table/Fig-6a]. Implant analogs were attached to open tray copings and soft tissue was reproduced employing soft tissue moulage material (Kerr, Orange, CA, USA), and maxillary and mandibular definitive working casts were poured

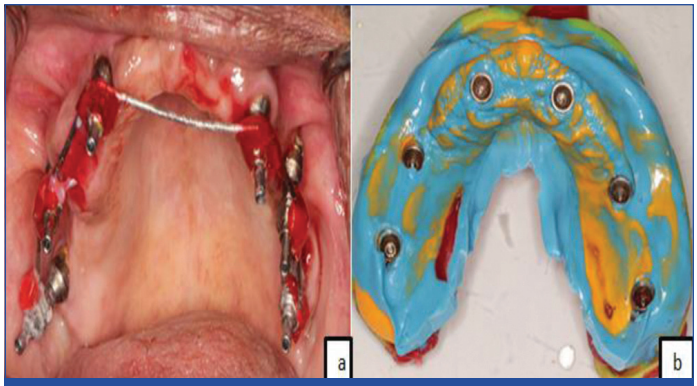

[Table/Fig-5]: a) Maxillary open tray impression with putty and light body material; b) Splinted impression copings.

using type-III dental stone (Microstone, Whip Mix Corp., Louisville, USA). Final cast and interocclusal bite were sent to laboratory for fabrication of screw retained acrylic prosthesis. The prostheses were adjusted to maintain occlusal point contacts in centric relation and anterior guidance in protrusion and group function in lateral excursions. Frontal profile with provisional prosthesis can be seen in [Table/Fig-6b].

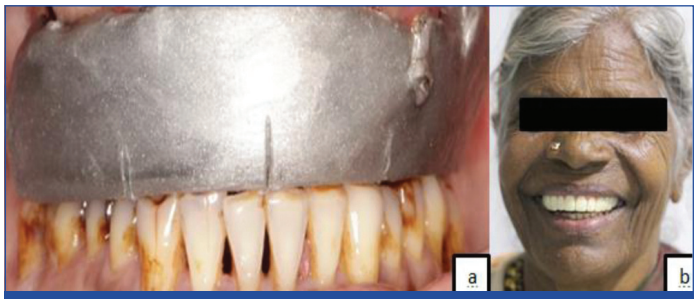

[Table/Fig-6]: a) Jaw relation record using Aluwax; b) Frontal profile with provisional prosthesis.

OPG was taken to confirm prosthesis fit. In each follow-up visit (after 1 day, 3 days, 1 week and 1 month), oral hygiene maintenance, prosthesis fit and healing assessed and were found to be satisfactory. After 3 months, provisional prosthesis was replaced with EXOCAD DMLS metal ceramic permanent fixed prosthesis adhering to previously mentioned steps [Table/Fig-7a-c]. Appropriate consent was obtained from the subject for using the images in the case report.

[Table/Fig-7]: a) Permanent fixed CADCAM prosthesis; b) OPG showing prosthesis loaded on 6 tilted implants; c) Frontal profile showing permanent CADCAM prosthesis.

A follow-up of implant and prosthetic survival was done up to 1 year. There were no peri-implant pockets or implant mobility or any associated soft tissue changes. No radiolucency was observed on the OPG. The prosthesis was functioning well and did not show any chipping, fracture, screw loosening or screw fracture.

DISCUSSION

Owing to maxillary sinus pneumatisation and osseous quality in the above patient, TTPHIL technique was used to obtain bicortical anchorage from nasal fossa, anterior wall of maxillary sinus and pterygomaxillary region minimising micromovements; thus, helping in better primary stabilisation [1-3]. Cortical engagement was possible due to longer, tilted implants. From biomechanical

point of view, anterio-posterior position of implants provided favourable inter-implant distance [4], improved bone implant contact area, eliminated cantilever and consequently lead to efficient load distribution [5]. Complete cantilever elimination can be attributed to engagement of pterygoid cortex which compensated for poor osseous structure [2,5]. From clinical perspective, the protocol followed fulfilled prerequisite for immediate functional loading of implants by achieving high primary stability [6]. Moreover, the technique eliminated need for grafts, bypassed vital structures and reduced treatment cost [1]. Thereby, this implant distribution aided in the restoration and replacement of 14 maxillary teeth including second molars that improved chewing efficiency as compared to 10-12 teeth of all-on-4 concept.

The stability and function of loaded implants depend on robust peri-implant mucosal barrier [7,8]. Reduction in postoperative pain, swelling, intraoperative bleeding, surgical time, soft and hard tissues preservation and maintenance of blood supply are some advantages of flapless technique [9]. Furthermore, frequent dis/reconnections compromised mucosal barrier causing apical migration and marginal bone loss [10,11]. Yamada J et al., concluded that flapless guided surgery for immediate loaded fixtures depicted predictable outcome and high implant survival rate in edentulous maxilla [12]. Additionally, Martinez CP et al., demonstrated that combining flapless surgery and subcrestal implant placement aids in preservation of crestal bone and increased osseointegration [13]. Subcrestal implant placement compensated for predictable bone loss by allowing bone regeneration and soft tissue growth by 1mm [14]. It facilitates osseointegration to abutment surface [15] and minimises thread exposure by formation of marginal tissue architecture enhancing aesthetic outcome [14,16].

For immediate functional loading in type-3 osseous bone quality, densification of surrounding bone is crucial for improved primary stability, bone-implant contact area and osseointegration. Drill surface aids in peripheral compaction of bone chips and debris through "osseodensification" [17]. Usage of single osteotomy drill reduced temperature [18], improved vascularization favouring bone regeneration [19]. Implant threads engage surrounding bone causing lateral condensation of spongy bone through "corticalisation" [20]. Hence, TTPHIL technique combined one stage, flapless surgery, single drill, subcrestal placement and basal cortical bone fixation allowing delivery of immediately loaded provisional fixed prosthesis by maintaining mucosal integration.

Biomechanical effects are compounded in poor bone quality and sinus pneumatisation [21]. Therefore to improve biomechanical efficiency, previous studies have advocated use of 6 implants for maxillary rehabilitation instead of conventional all-on-4 technique [22,23]. Nonetheless, these techniques cannot completely eliminate cantilever. Employing zygomatic implants can be invasive, technique sensitive and limited by anatomy of zygomatic bone [24]. One year follow-up, showing satisfactory clinical results elucidate in the direction of validation of TTPHIL technique in atrophic maxilla. Nevertheless, its use in more number of patients and long-term clinical and radiographic follow-up is needed for better validation of technique.

CONCLUSION(S)

The presented technique eliminated cantilever for maxillary rehabilitation using graftless, guided, single osteotomy, tilted six implants and 14 teeth, and was able to improve the clinical ease, patient acceptance and chewing efficiency in a single appointment. The patient was satisfied with implants and prosthesis, demonstrated good healing leading to overall success of implants and prosthesis at one year follow-up. By harnessing benefits of various concepts in implantology, this technique has been successful in providing patient and clinician centric treatment of severely atrophic maxilla.

REFERENCES

[1] Krekmanov L, Kahn M, Rangert B, Lindström H. Tilting of posterior mandibular and maxillary implants for improved prosthesis support. Int J Oral Maxillofac Implants. 2000;15:405-14.

[2] Salinas-Goodier C, Rojo R, Murillo-González J, Prados-Frutos JC. Three-dimensional descriptive study of the pterygomaxillary region related to pterygoid implants: A retrospective study. Scientific Reports. 2019;9(1):16179. DOI: 10.1038/s41598-019-52672-x.

[3] Han CH, Mangano F, Mortellaro C, Park KB. Immediate loading of tapered implants placed in postextraction sockets and healed sites. J Craniofac Surg. 2016;27:1220-27.

[4] Maló P, de Araújo Nobre M, Lopes A, Rodrigues R. Tilted long implants in immediate function. Clin Implant Dent Relat Res. 2015;17:e134-e142.

[5] Wang F, Huang W, Wu Y, Montanero-Fernandez J, Sheridan RA, Wang HL, et al. Accuracy of cone beam computed tomography grayscale density in determining bone architecture in the posterior mandible: an in vivo study with microcomputed tomography validation. Int J Oral Maxillofac Implants. 2017;32(5):1074-79.

[6] Maló P, Rangert B, Dvärsäter L. Immediate function of Brånemark implants in the esthetic zone: a retrospective clinical study with 6 months to 4 years of follow-up. Clin Implant Dent Relat Res. 2000;2(3):138-46.

[7] Perrotti V, Zhang D, Liang A, Wong J, Quaranta A. The effect of one-abutment at one-time on marginal bone loss around implants placed in healed bone: A systematic review of human studies. Implant Dent. 2019;28(6):603-12. DOI: 10.1097/id.0000000000000931.

[8] Van der Zee E, Oosterveld P, Van Waas MA. Effect of GBR and fixture installation on gingiva and bone levels at adjacent teeth. Clin Oral Implants Res. 2004;15(1):62-65.

[9] Brodala N. Flapless surgery and its effect on dental implant outcomes. Int J Oral Maxillofac Implants. 2009;24:118-25.

[10] Borie M, Lecloux G, Bosshardt D, Barrantes A, Haugen HJ, Lambert F, et al. Peri-implant soft tissue integration in humans – influence of materials: A study protocol for a randomised controlled trial and a pilot study results. Contemp Clin Trials Commun. 2020;19:100643. https://doi.org/10.1016/j.conctc.2020.100643.

[11] Byrne G. Outcomes of one-stage versus two-stage implant placement. J Am Dent Assoc. 2010;141(10):1257-58.

[12] Yamada J, Kori H, Tsukiyama Y, Matsushita Y, Kamo M, Koyano K. Immediate loading of complete-arch fixed prostheses for edentulous maxillae after flapless guided implant placement: a 1-year prospective clinical study. Int J Oral Maxillofac Implants. 2015;30(1):184-93.

[13] érez-Albacete Martínez C, Vlahović Z, Šćepanović M, Videnović G, Barone A, Calvo-Guirado JL. Submerged flapless technique vs. conventional flap approach for implant placement: experimental domestic pig study with 12-month follow-up. Clin Oral Implants Res. 2016;27(8):964-68 doi: 10.1111/clr.12665.

[14] Koh RU, Oh TJ, Rudek I, Neiva GF, Misch CE, Rothman ED, et al. Hard and soft tissue changes after crestal and subcrestal immediate implant placement. J Periodontol. 2011;82(8):1112-20.

[15] Degidi M, Perrotti V, Shibli JA, Novaes AB, Piattelli A, Iezzi G. Equicrestal and subcrestal dental implants: a histologic and histomorphometric evaluation of nine retrieved human implants. J Periodontol. 2011;82(5):708-15.

[16] Novaes AB Jr, Barros RR, Muglia VA, Borges GJ. Influence of interimplant distances and placement depth on papilla formation and crestal resorption: a clinical and radiographic study in dogs. J Oral Implantol. 2009;35(1):18-27. doi: 10.1563/1548-1336-35.1.18.

[17] Podaropoulos L. Increasing the stability of dental implants: the concept of osseodensification. Balk J Dent Med. 2017;21(3):133-40. https://doi.org/10.1515/bjdm-2017-0023

[18] Bettach R, Taschieri S, Boukhris G, Del Fabbro M. Implant survival after preparation of the implant site using a single bur: a case series. Clin Implant Dent Relat Res. 2015;17(1):13-21.

[19] Galindo-Moreno P, Nilsson P, King P, Becktor J, Speroni S, Schramm A, et al. Clinical and radiographic evaluation of early loaded narrow diameter implants – 1-year follow-up. Clin Oral Impl Res. 2012;23:609-16.

[20] Ali SM, Othman KS, Samad AA, Kh Mahmud P. Comparison between basal and conventional implants as a treatment modality in atrophied ridges. J Dent Implant Res. 2019;38(2):48-54.

[21] Torrecillas-Martínez L, Monje A, Lin GH, Suarez F, Ortega-Oller I, Galindo-Moreno P, et al. Effect of cantilevers for implant-supported prostheses on marginal bone loss and prosthetic complications: systematic review and meta-analysis. Int J Oral Maxillofac Implants. 2014;29(6):1315-21.

[22] Testori T, Del Fabbro M, Capellini M, Zuffetti F, Francetti L, Weinstein RL. Immediate occlusal loading and tilted implants for the rehabilitation of the atrophic edentulous maxilla: 1-year interim results of a multicenter prospective study. Clin Oral Implants Res. 2008;19:227-32.

[23] Pomares C. A retrospective clinical study of edentulous patients rehabilitated according to the "all-on-four" or the "all-on-six" immediately function concept. Eur J Oral Implantol. 2009;2(1):55-60.

[24] Dominguez EA, Guerrero C, Shehata E, Van Sickels JE. Zygoma implants or sinus lift for the atrophic maxilla with a dentate mandible. Dent Clin N Am. 2019;63(3):499-513.

PARTICULARS OF CONTRIBUTORS:

1. Professor, Department of Prosthodontia, Panineeya Dental College, Hyderabad, Telangana, India.
2. Reader, Department of Pedodontia, S.B. Patil Dental College, Hyderabad, Telangana, India.
3. Prosthodontist, Department of Prosthodontia, Institute for Dental Implantology, Hyderabad, Telangana, India.

NAME, ADDRESS, E-MAIL ID OF THE CORRESPONDING AUTHOR:
Venkata Ratna Nag Puppala,
Uma Devraj Villa, Banjara Hills, Road No. 10, Hyderabad, Telangana, India.
E-mail: tdspublication@gmail.com

PLAGIARISM CHECKING METHODS: [Jain H et al.]

- Plagiarism X-checker: Dec 30, 2020
- Manual Googling: Feb 20, 2021
- iThenticate Software: Mar 22, 2021 (6%)

ETYMOLOGY: Author Origin

AUTHOR DECLARATION:

- Financial or Other Competing Interests: None
- Was informed consent obtained from the subjects involved in the study? Yes
- For any images presented appropriate consent has been obtained from the subjects. Yes

Date of Submission: **Dec 29, 2020**
Date of Peer Review: **Jan 22, 2021**
Date of Acceptance: **Mar 01, 2021**
Date of Publishing: **May 01, 2021**