Volume 11, No. 1

April 2019

JIACD

The Journal of Implant & Advanced Clinical Dentistry

Surgical Planning using 3D Printed Models

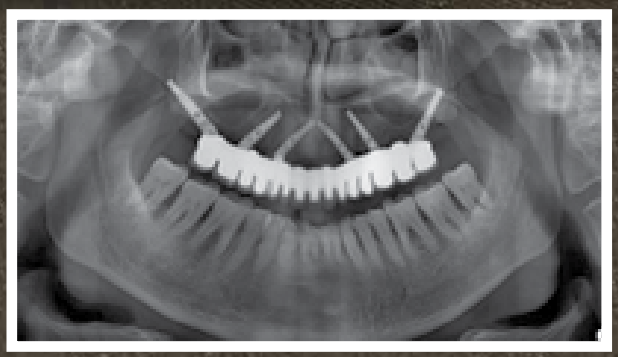

Atrophic Maxilla Rehap with Tilted Implants

JIACD
The Journal of Implant & Advanced Clinical Dentistry

ATTENTION PROSPECTIVE AUTHORS

JIACD wants to publish your article!

For complete details regarding publication in JIACD, please refer to our author guidelines at the following link:
jiacd.com/author-guidelines
or email us at:
editors@jicad.com

The Best Things in Life Are FREE!



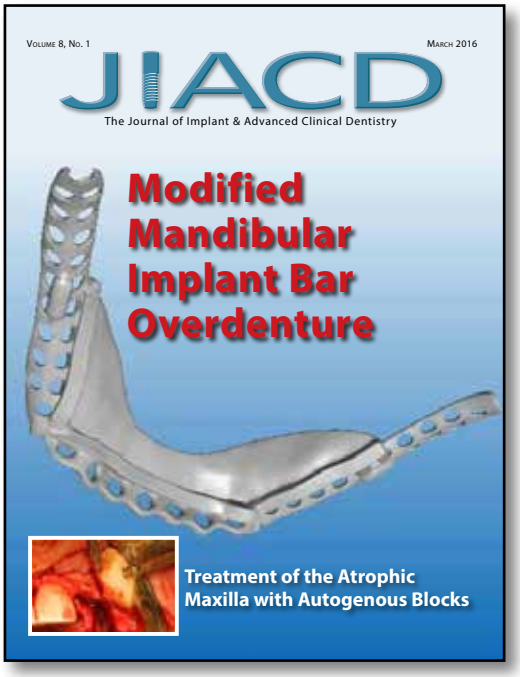

Subscribe now to enjoy articles **free of charge** that will benefit you, the actively practicing dental provider. With each JIACD issue, readers are afforded the opportunity to assess clinical techniques, cases, literature reviews, and expert commentary that can immediately impact their daily dental practice.

Email notification when new issues are available online.

Start your FREE subscription today at www.jiacd.com

JIACD
The Journal of Implant & Advanced Clinical Dentistry
Volume 11, No. 1 • Apirl 2019

Table of Contents

6 **Surgical Planning using 3D Printed Anatomical Models in a Complex Case of Dental Implants**
Mohammed Husain

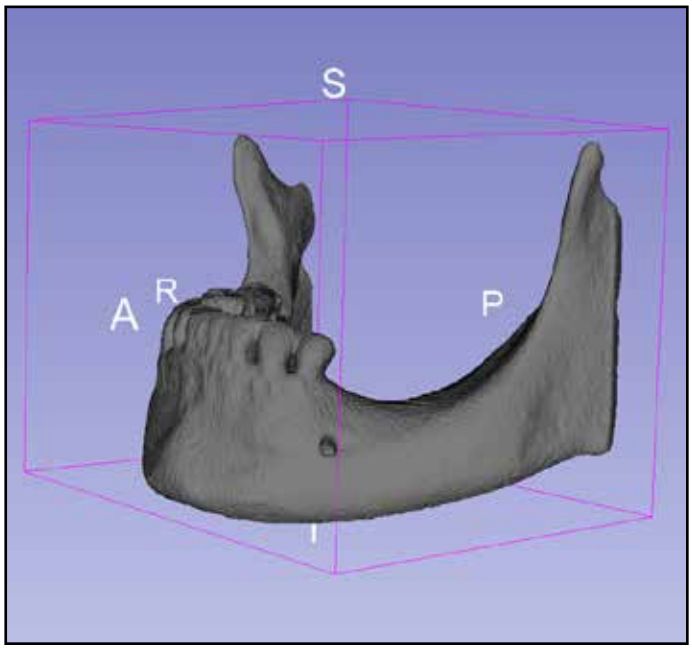

14 **Tilted Implant Placement for Rehabilitation of Severe Atrophic Maxilla Supported by Finite Element Analysis**
Dr. Venkat Ratna Nag, Dr. P. Sarika,
Dr. Tejashree Bhagwatkar,
Dr. Vasantha Dhara

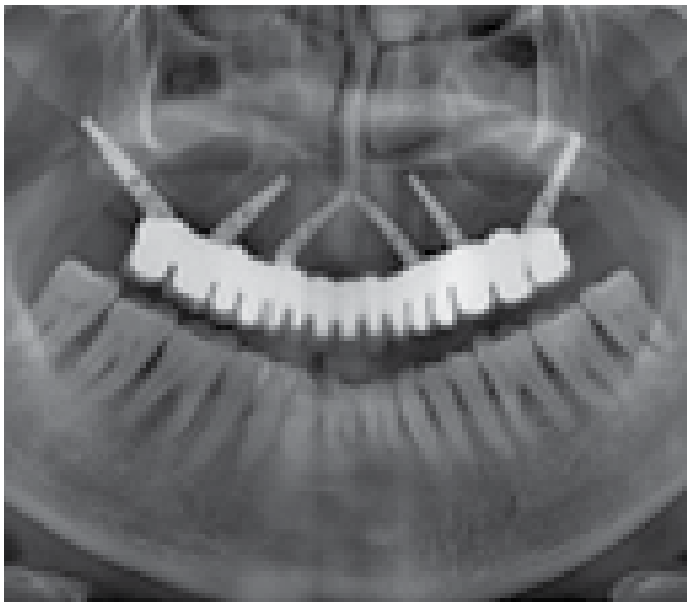

JIACD
The Journal of Implant & Advanced Clinical Dentistry
Volume 11, No. 1 • April 2019

Table of Contents

28 **A Novel Procedure of Regaining Aesthetics with Implants and Autogenous Dentin Graft: A Report of Three Cases with One Year of Follow Up**
Dr. Verma Kamal, Dr. Viswambaran, Dr. Yadav Rajesh Kumar, Dr. Verma Rashima

JIACD
The Journal of Implant & Advanced Clinical Dentistry
Volume 11, No. 1 • April 2019

Publisher
LC Publications

Design
Jimmydog Design Group
www.jimmydog.com

Production Manager
Stephanie Belcher
336-201-7475 • sbelcher@triad.rr.com

Copy Editor
JIACD staff

Digital Conversion
JIACD staff

Internet Management
InfoSwell Media

Subscription Information: Annual rates as follows: Non-qualified individual: $99(USD) Institutional: $99(USD). For more information regarding subscriptions, contact info@jiacd.com or 1-888-923-0002.

Advertising Policy: All advertisements appearing in the Journal of Implant and Advanced Clinical Dentistry (JIACD) must be approved by the editorial staff which has the right to reject or request changes to submitted advertisements. The publication of an advertisement in JIACD does not constitute an endorsement by the publisher. Additionally, the publisher does not guarantee or warrant any claims made by JIACD advertisers.

For advertising information, please contact:
info@JIACD.com or 1-888-923-0002

Manuscript Submission: JIACD publishing guidelines can be found at http://www.jiacd.com/author-guidelines or by calling 1-888-923-0002.

Copyright © 2019 by LC Publications. All rights reserved under United States and International Copyright Conventions. No part of this journal may be reproduced or transmitted in any form or by any means, electronic or mechanical, including photocopying or any other information retrieval system, without prior written permission from the publisher.

Disclaimer: Reading an article in JIACD does not qualify the reader to incorporate new techniques or procedures discussed in JIACD into their scope of practice. JIACD readers should exercise judgment according to their educational training, clinical experience, and professional expertise when attempting new procedures. JIACD, its staff, and parent company LC Publications (hereinafter referred to as JIACD-SOM) assume no responsibility or liability for the actions of its readers.

Opinions expressed in JIACD articles and communications are those of the authors and not necessarily those of JIACD-SOM. JIACD-SOM disclaims any responsibility or liability for such material and does not guarantee, warrant, nor endorse any product, procedure, or technique discussed in JIACD, its affiliated websites, or affiliated communications. Additionally, JIACD-SOM does not guarantee any claims made by manufact-urers of products advertised in JIACD, its affiliated websites, or affiliated communications.

Conflicts of Interest: Authors submitting articles to JIACD must declare, in writing, any potential conflicts of interest, monetary or otherwise, that may exist with the article. Failure to submit a conflict of interest declaration will result in suspension of manuscript peer review.

Erratum: Please notify JIACD of article discrepancies or errors by contacting editors@JIACD.com

JIACD (ISSN 1947-5284) is published on a monthly basis by LC Publications, Las Vegas, Nevada, USA.

JIACD
The Journal of Implant & Advanced Clinical Dentistry

Founder, Co-Editor in Chief
Dan Holtzclaw, DDS, MS

Co-Editor in Chief
Leon Chen, DMD, MS, DICOI, DADIA

Tara Aghaloo, DDS, MD
Faizan Alawi, DDS
Michael Apa, DDS
Alan M. Atlas, DMD
Charles Babbush, DMD, MS
Thomas Balshi, DDS
Barry Bartee, DDS, MD
Lorin Berland, DDS
Peter Bertrand, DDS
Michael Block, DMD
Chris Bonacci, DDS, MD
Hugo Bonilla, DDS, MS
Gary F. Bouloux, MD, DDS
Ronald Brown, DDS, MS
Bobby Butler, DDS
Nicholas Caplanis, DMD, MS
Daniele Cardaropoli, DDS
Giuseppe Cardaropoli DDS, PhD
John Cavallaro, DDS
Jennifer Cha, DMD, MS
Leon Chen, DMD, MS
Stepehn Chu, DMD, MSD
David Clark, DDS
Charles Cobb, DDS, PhD
Spyridon Condos, DDS
Sally Cram, DDS
Tomell DeBose, DDS
Massimo Del Fabbro, PhD
Douglas Deporter, DDS, PhD
Alex Ehrlich, DDS, MS
Nicolas Elian, DDS
Paul Fugazzotto, DDS
David Garber, DMD
Arun K. Garg, DMD
Ronald Goldstein, DDS
David Guichet, DDS
Kenneth Hamlett, DDS
Istvan Hargitai, DDS, MS
Michael Herndon, DDS
Robert Horowitz, DDS
Michael Huber, DDS
Richard Hughes, DDS
Miguel Angel Iglesia, DDS
Mian Iqbal, DMD, MS
James Jacobs, DMD
Ziad N. Jalbout, DDS
John Johnson, DDS, MS
Sascha Jovanovic, DDS, MS
John Kois, DMD, MSD
Jack T Krauser, DMD
Gregori Kurtzman, DDS
Burton Langer, DMD
Aldo Leopardi, DDS, MS
Edward Lowe, DMD
Miles Madison, DDS
Lanka Mahesh, BDS
Carlo Maiorana, MD, DDS
Jay Malmquist, DMD
Louis Mandel, DDS
Michael Martin, DDS, PhD
Ziv Mazor, DMD
Dale Miles, DDS, MS
Robert Miller, DDS
John Minichetti, DMD
Uwe Mohr, MDT
Dwight Moss, DMD, MS
Peter K. Moy, DMD
Mel Mupparapu, DMD
Ross Nash, DDS
Gregory Naylor, DDS
Marcel Noujeim, DDS, MS
Sammy Noumbissi, DDS, MS
Charles Orth, DDS
Adriano Piattelli, MD, DDS
Michael Pikos, DDS
George Priest, DMD
Giulio Rasperini, DDS
Michele Ravenel, DMD, MS
Terry Rees, DDS
Laurence Rifkin, DDS
Georgios E. Romanos, DDS, PhD
Paul Rosen, DMD, MS
Joel Rosenlicht, DMD
Larry Rosenthal, DDS
Steven Roser, DMD, MD
Salvatore Ruggiero, DMD, MD
Henry Salama, DMD
Maurice Salama, DMD
Anthony Sclar, DMD
Frank Setzer, DDS
Maurizio Silvestri, DDS, MD
Dennis Smiler, DDS, MScD
Dong-Seok Sohn, DDS, PhD
Muna Soltan, DDS
Michael Sonick, DMD
Ahmad Soolari, DMD
Neil L. Starr, DDS
Eric Stoopler, DMD
Scott Synnott, DMD
Haim Tal, DMD, PhD
Gregory Tarantola, DDS
Dennis Tarnow, DDS
Geza Terezhalmy, DDS, MA
Tiziano Testori, MD, DDS
Michael Tischler, DDS
Tolga Tozum, DDS, PhD
Leonardo Trombelli, DDS, PhD
Ilser Turkyilmaz, DDS, PhD
Dean Vafiadis, DDS
Emil Verban, DDS
Hom-Lay Wang, DDS, PhD
Benjamin O. Watkins, III, DDS
Alan Winter, DDS
Glenn Wolfinger, DDS
Richard K. Yoon, DDS

Surgical Planning using 3D Printed Anatomical Models in a Complex Case of Dental Implants

Mohammed Husain, DDS[1]

Abstract

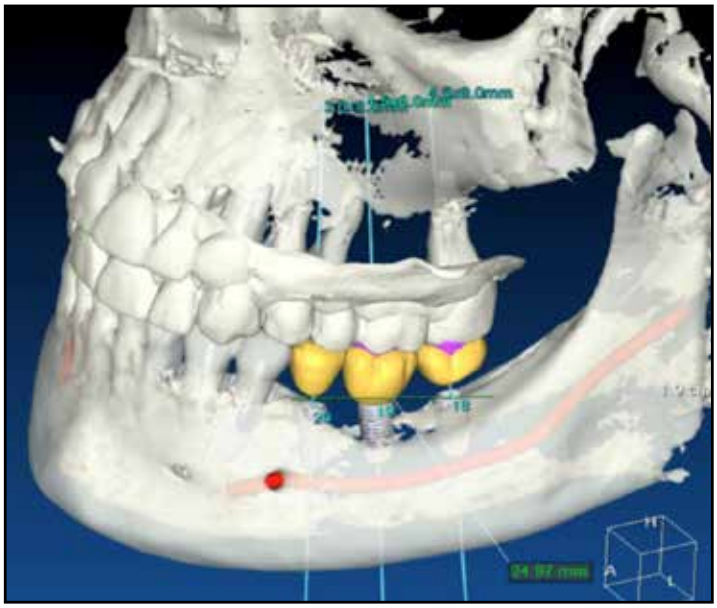

Dental implant therapy in edentulous patient demonstrating significant alveolar bone loss can be challenging and may require augmentation using autogenous block grafts such as that from the mandibular ramus. Harvesting of autogenous grafts entails the possibility of additional morbidity, including the risk of mandibular nerve injury. This case report explores the usefulness of 3D printed anatomic models as an adjunctive tool in pre-surgical planning to minimize the risk of additional morbidity associated with autogenous ramus grafting. Reported benefits of the 3D printed anatomical model lied in the areas of patient communication, improved morphological assessment and reduced outcome risk.

KEY WORDS: Treatment planning, digital dentistry, 3D printing, ramus, bone graft

1. Assistant Clinical Professor, Section of Oral and Maxillofacial Radioogy,
UCLA School of Dentistry, Los Angeles, California, USA

INTRODUCTION

Dental implant therapy for edentulous patients with marked alveolar bone deficiency can be a challenge. The presence of significant bony defects, or poor quality alveolar bone can compromise the long-term stability and success of dental implants.[1,2] Fortunately, a number of osseous augmentation techniques are available to predictably alter bone height and width, allowing patients with even moderate-severe alveolar atrophy to be eligible for implant therapy. Among these augmentation techniques is the use of an autogenous block grafts from the mandibular ramus.

Autogenous bone grafts are generally seen to be the gold standard for alveolar ridge augmentation on account of their biocompatibility and osteoinductivity and have a predictable outcome.[2-13] In particular, mandibular block grafts are favored for being primarily cortical bone, which exhibit reduced resorption and show good osseointegration at short healing times.[6,14] Furthermore, they are "locally" available, with the donor and recipient site in the same surgical field, reducing operative and anesthesia time relative to extra-oral bone harvesting.[7]

Autogenous bone harvesting techniques, in requiring a 2nd surgical site however, do typically entail some increased morbidity relative to allogeneic techniques. For mandibular block grafts, these include an increased likelihood of sensory disturbances of the overlying mucosa and skin, postoperative pain and swelling at the site of surgery and possible loss of adjacent tooth vitality.[15] Of the common sites of autogenous bone harvesting (mandibular symphysis, ramus, iliac crest and calvarium), grafts from the ramus may be favored for having the least associated morbidity.[8,16]

Given the proximity of the mandibular canal to grafts harvested from the mandibular ramus, knowledge of the inferior alveolar canal anatomy is critical to prevent nerve injury.[6] 3D Cone Beam CT (CBCT) imaging of the mandibular ramus plays an important preoperative role in understanding the positioning of the mandibular canal, and quantifying the amount of available bone that can be safely grafted.[17] A more in-depth and direct understanding of the relevant anatomy of the mandibular ramus may now be obtained by supplementing 3D imaging with the fabrication of 3D printed anatomical models. These dimensionally accurate models are based on CBCT imaging data, and give the surgeon an opportunity to directly interact with a physical replica of the patient's anatomy, making it easier to understand the morphological limitations at the site of interest. They also offer the opportunity to perform hands-on surgical planning, including a full mock surgery, prior to the actual procedure. Surgeons using stereolithographic models have reported reduced operative time, improved treatment planning, and more predictable outcomes.[18,19]

3D printed stereolithographic models are produced from most types of 3D imaging data, such as that from a CBCT scanner. The imaging data, must undergo a post-acquisition segmentation process in which the area of interest is separated from adjacent tissues. In the context of dental applications, this usually entails separating bone from neighboring soft tissues. This segmentation process is done in specialized 3D visualization software. Once complete, a three-dimensional digital surface model of the area of interest can be created in a file format (STL) acceptable for 3D printing.

3D printing, technically known as additive manufacturing, is a process by which a three-

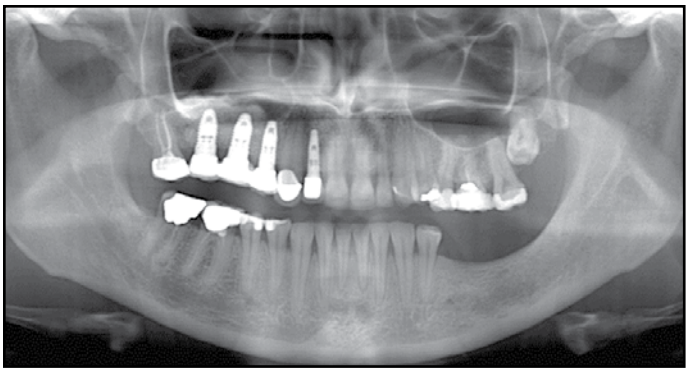

Figure 1: Pre-surgical radiograph showing deficient left posterior mandible.

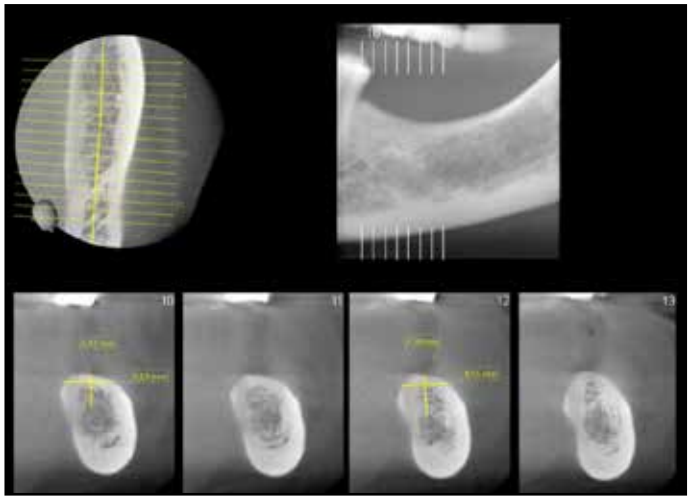

Figure 2: Pre-surgical CBCT showing axial and sagittal views of left posterior mandible.

dimensional object is built by the successive layering of material under computerized control. Stereolithography is one among many different types of 3D printing, known for its ability to create complex shapes with high resolution.20 It is distinguished from other types of 3D printing by the use of an ultraviolet laser which successively cures thin layers of photopolymer resin onto a build platform to create a 3D object.20

Applications of 3D printing in dentistry are increasing. Surgical guides for enhanced precision of dental implant placement are commonly produced using stereolithography. Anatomical models for mandibular reconstructive surgery have long been used for the pre-bending of reconstructive plates prior to surgery. The pre-bending of titanium meshes for guided bone formation is also sometimes performed on anatomical models. We present a novel application of a 3D printed anatomical model in a complex case of implant rehabilitation involving bone harvesting from the mandibular ramus.

CASE REPORT

A 40-year-old healthy female patient presented with the chief complaint of esthetic compromise and difficulty chewing on her left side due to tooth loss lasting over 25 years. She had no significant medical history or systemic disease. Intraoral examination showed moderate supraeruption of teeth #13-15. The panoramic radiograph showed moderate loss of vertical height in the posterior left mandible in the area of teeth #18-20 (Figure 1). CBCT imaging of the posterior left mandible was acquired with the Morita Accuitomo 170 scanner (J. Morita, Kyoto, Japan) using a 4 cm x 4 cm FOV. The scan showed a superior course of the mandibular canal through the left mandibular body, leaving approximately 3-5 mm of available alveolar ridge height for implants (Figure 2). Virtual (in-silico) treatment planning on the CBCT scan in this area also demonstrated varied degrees of alveolar bone deficiency (Figure 3).

The final treatment plan for the patient included alveolar and occlusal plane repositioning in the posterior left maxillary arch and implant sup-

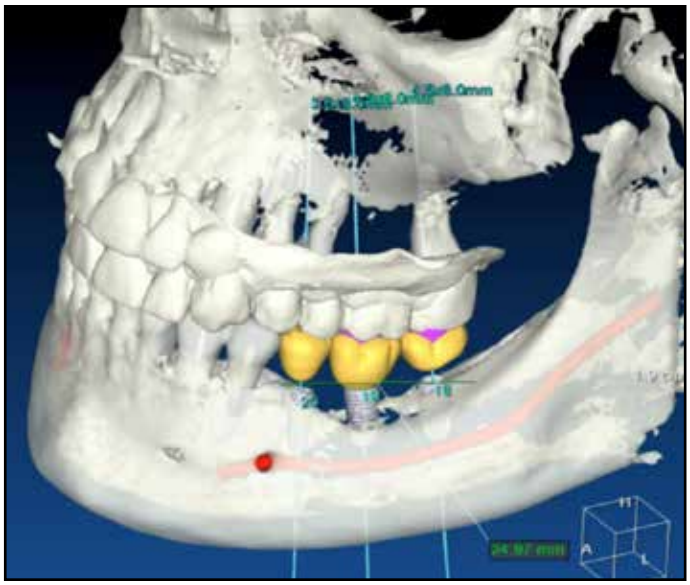

Figure 3: Implant planning of left posterior mandible.

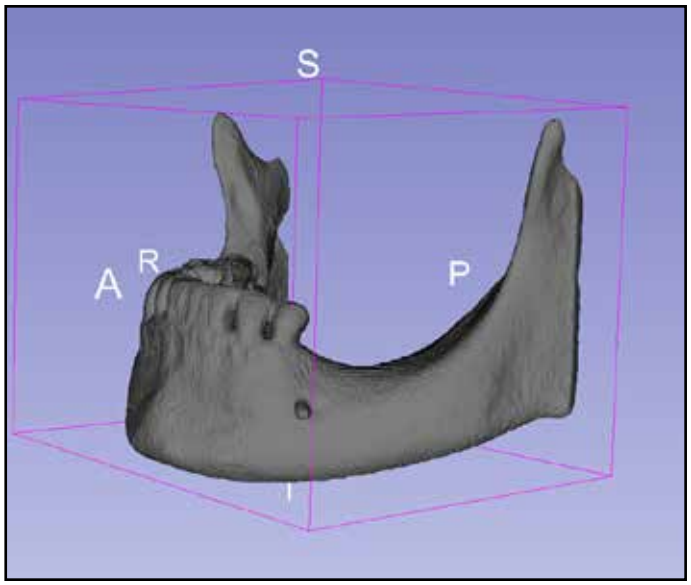

Figure 4: Digital representation of planned 3D printed model.

Figure 5: 3D printed model of mandible.

Figure 6: Mock ramus bone harvesting surgery was performed on the anatomic model.

ported restorations in the opposing left posterior mandible. In preparation for the dental implants, vertical alveolar ridge augmentation in the left mandible was planned using a mandibular ramus graft from the contralateral side. However, buccal positioning of the mandibular canal in the area of the donor site raised concerns regarding the potential of mandibular canal violation during the bone harvesting surgery. 3D printed anatomic models were sought for hands-on surgical plan-

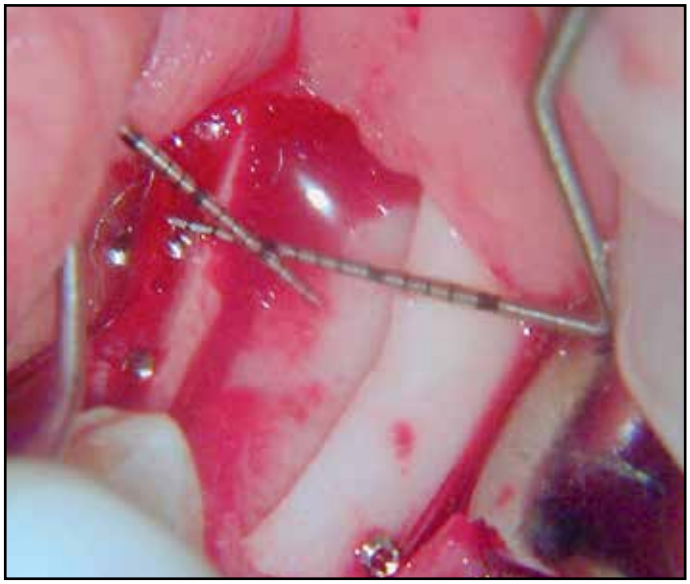

Figure 7: Right-sided ramus graft was harvested, and onlay grafts were placed in the area of missing teeth #18-20.

Figure 8: CBCT imaging performed at 5 months. Evidence of block graft osseointegration was noted.

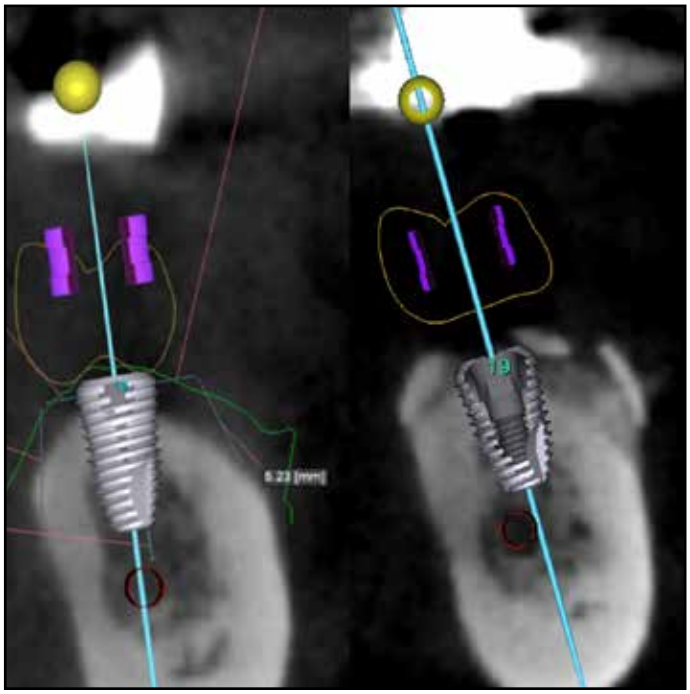

Figure 9: Virtual (In silico) treatment planning was performed on the 5-month follow up CBCT scan.

ning and more precise visualization of the mandibular nerve to avoid injury. To create an appropriate anatomic model, larger FOV CBCT imaging was required to encompass the ascending rami. This was done utilizing a 10 cm x 10 cm FOV on the Morita Accuitomo 170 CBCT scanner.

The CBCT imaging data (DICOM) from the large FOV scan was exported and post-processed in two stages using two different 3D visualization software programs. The first stage of post-processing was done in the MD studio module of the Invivo 5 (Anatomage, San Jose, CA) software, where the specialized "pipe" tool was used for the segmentation of the mandibular canal. After the mandibular canal was segmented, the DICOM data was reexported and uploaded into Slicer. In this 2nd stage, the remainder of the mandible was segmented from the adjacent soft tissue, and a 3D surface model of the mandible was created and exported as an STL file (Figure 4). The 3D surface model (STL) was

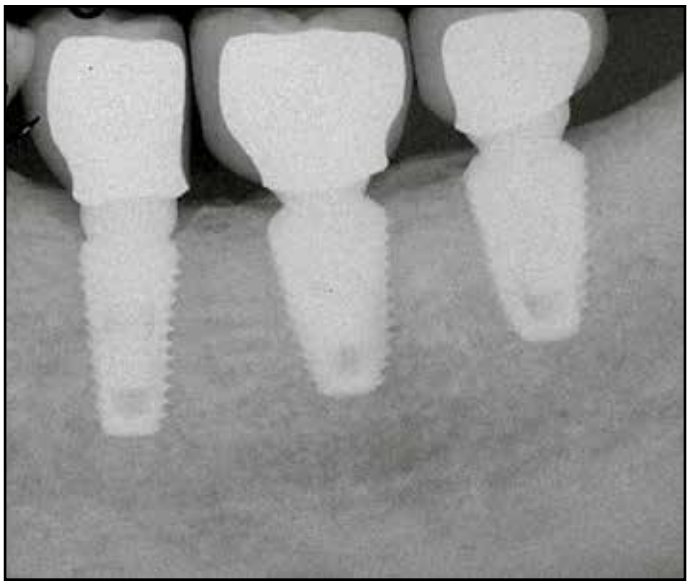

Figure 10: One year follow up PA imaging of surgical site.

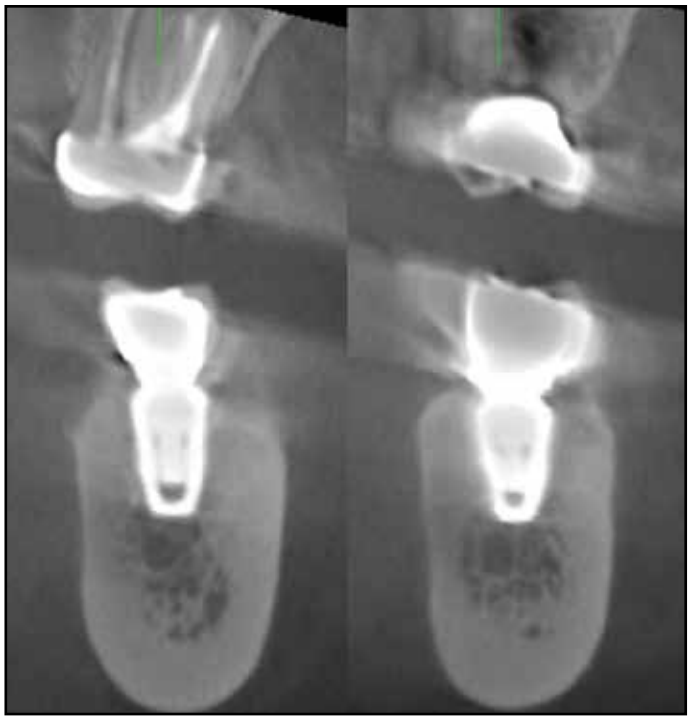

Figure 11: Two year follow up CBCT imaging of surgical site.

then sent to the Formlabs 1+ SLA printer (Formlabs, Somerville, MA) for 3D printing (Figure 5).

The final anatomic model was printed using a transparent resin that would allow clear visualization of the mandibular canal. Once in the hands of the surgeon, a mock ramus bone harvesting surgery was performed on the anatomic model (Figure 6). This allowed him to verify clearance of his osteotomy from the mandibular canal. Also, surgical templates of the size and shape of the block graft were developed from the anatomical model to guide the actual surgery.

Having comprehensively planned the bone harvesting surgery, the actual procedure proceeded without complication. A right-sided ramus graft was harvested, and onlay grafts were placed in the area of missing teeth #18-20 (Figure 7). The onlay graft was fixated with multiple surgical screws. The patient experienced mild-moderate swelling and discomfort bilaterally following surgery, which resolved in approximately 2 weeks. No report of neurosensory alteration, loss of tooth vitality or other significant complication occurred following the procedure. After grafting, the patient returned in 5 months to evaluate the osseointegration of the graft. At this time, CBCT imaging was again performed, and evidence of block graft osseointegration was noted (Figure 8).

Virtual (In silico) treatment planning was performed on the 5-month follow up CBCT scan (Figure 9), to verify adequate gain in alveolar volume necessary to proceed with implant placement. The virtual plan was then exported to fabricate a surgical guide, in order to better execute the planned implant positioning during surgery. Using the surgical guide, three Dentium Superline implants (Dentium Co., Suwon, Korea) measuring 4.5 x 8 mm, 5 x 8 mm and 5 x 8 mm were placed at the areas of miss-

ing teeth #18-20. One year follow up PA imaging (Figure 10) and two year follow up CBCT imaging (Figure 11) show successful osseointegration, screw removal and final restoration.

DISCUSSION

Alveolar bone deficiency is a common sequela of periodontal disease and tooth loss. In such cases, rehabilitation with dental implants may involve alveolar ridge augmentation using autogenous mandibular block grafts. Autogenous grafts, such as that harvested from the mandibular ramus, are often preferred for their osteoinductive and osteogenic potential[12]. Autogenous grafting, however, entails the possibility of additional morbidity. In particular, for ramus grafts concern arises about the proximity of the mandibular canal. 3D printed anatomic models in conjunction with CBCT imaging, may minimize the additional morbidity associated with autogenous grafting by allowing for better visualization of mandibular morphology and more comprehensive surgical planning.

In the case presented, the surgeon reported that the use of the stereolithographic anatomic model was highly beneficial in obtaining a successful outcome. Benefits were described largely in four areas: patient communication, treatment planning, surgical execution and the predictability of the outcome. The anatomic model served as an effective communication tool that gave the patient the ability to visualize directly what is otherwise abstract and difficult for a layperson to understand on radiographs. The morphology of the edentulous area and the location of the mandibular canal were easily comprehensible to the patient on a life-sized model. As a result, the patient could better understand the limits and risks of surgery as well as its advantages, enabling her to offer more meaningful consent to the proposed treatment plan.

From a treatment planning perspective, the surgeon found it easier to appreciate the limitations of the patient's mandibular morphology through direct visualization on an anatomic model, particularly as it related to the position of the mandibular canal. This allowed the surgeon to set appropriate expectations for surgery, and treatment plan more appropriately in advance of the procedure.

The ability to perform a mock surgery on the anatomic model was seen to have additional benefits in improving intra-surgical control and predictability of the outcome. The mock surgery offered an opportunity to test the viability of the surgical plan, reducing outcome risk. It also offered the opportunity to develop custom surgical templates of the block grafts to guide the actual bone harvesting surgery. Finally, performing a simulation surgery on a dimensionally accurate model improved the surgeon's confidence, accuracy and efficiency during surgery, factors important for the success of the final outcome.

Correspondence:
Dr. Mahammed Husain
mhusain@dentistry.ucla.edu

Disclosure:
The author reports no conflicts of interest with anything in this article.

References

1. Aghaloo TL, Moy PK. Which hard tissue augmentation techniques are the most successful in furnishing bony support for implant placement? International Journal of Oral & Maxillofacial Implants. 2007;22(7).

2. Spin-Neto R, Stavropoulos A, Pereira LAVD, Marcantonio E, Wenzel A. Fate of autologous and fresh-frozen allogeneic block bone grafts used for ridge augmentation. A CBCT-based analysis. Clinical oral implants research. 2013;24(2):167-173.

3. Nowzari H, Aalam A-A. Mandibular cortical bone graft part 2: surgical technique, applications, and morbidity. Compendium of continuing education in dentistry (Jamesburg, NJ: 1995). 2007;28(5):274-280; quiz 281-272.

4. Capelli M. Autogenous bone graft from the mandibular ramus: a technique for bone augmentation. International Journal of Periodontics and Restorative Dentistry. 2003;23(3):277-286.

5. D'addona A, Nowzari H. Intramembranous autogenous osseous transplants in aesthetic treatment of alveolar atrophy. Periodontology 2000. 2001;27(1):148-161.

6. Misch CM. Use of the mandibular ramus as a donor site for onlay bone grafting. Journal of Oral Implantology. 2000;26(1):42-49.

7. Clavero J, Lundgren S. Ramus or chin grafts for maxillary sinus inlay and local onlay augmentation: comparison of donor site morbidity and complications. Clinical implant dentistry and related research. 2003;5(3):154-160.

8. Nkenke E, Neukam FW. Autogenous bone harvesting and grafting in advanced jaw resorption: morbidity, resorption and implant survival. Eur J Oral Implantol. 2014;7(Suppl 2):S203-217.

9. Khoury F, Khoury C. Mandibular bone block grafts: diagnosis, instrumentation, harvesting techniques and surgical procedures. In: Bone augmentation in oral implantology. Quintessence, Berlin; 2007.

10. Toscano N, Shumaker N, Holtzclaw D. The art of block grafting: A review of the surgical protocol for reconstruction of alveolar ridge deficiency. J Implant Adv Clin Dent. 2010;2(2):45-66.

11. Gultekin BA, Bedeloglu E, Kose TE, Mijiritsky E. Comparison of Bone Resorption Rates after Intraoral Block Bone and Guided Bone Regeneration Augmentation for the Reconstruction of Horizontally Deficient Maxillary Alveolar Ridges. BioMed research international. 2016;2016:4987437.

12. Khoury F, Antoun H, Missika P. Bone augmentation in oral implantology. Quintessence; 2007.

13. Verdugo F, Simonian K, Smith McDonald R, Nowzari H. Quantitation of Mandibular Symphysis Volume as a Source of Bone Grafting. Clinical Implant Dentistry and Related Research. 2010;12(2):99-104.

14. Khoury F. Augmentation of the sinus floor with mandibular bone block and simultaneous implantation: a 6-year clinical investigation. The International journal of oral & maxillofacial implants. 1999;14(4):557-564.

15. Cordaro L, Torsello F, Tindara Miuccio M, Mirisola di Torresanto V, Eliopoulos D. Mandibular bone harvesting for alveolar reconstruction and implant placement: subjective and objective cross-sectional evaluation of donor and recipient site up to 4 years. Clinical oral implants research. 2011;22(11):1320-1326.

16. Scheerlinck E, Laura M, Muradin M, et al. Donor site complications in bone grafting: comparison of iliac crest, calvarial, and mandibular ramus bone. International Journal of Oral & Maxillofacial Implants. 2013;28(1).

17. Verdugo F, Simonian K, McDonald RS, Nowzari H. Quantitation of Mandibular Ramus Volume as a Source of Bone Grafting. Clinical Implant Dentistry and Related Research. 2009;11:e32-e37.

18. Erickson DM, Chance D, Schmitt S, Mathts J. An opinion survey of reported benefits from the use of stereolithographic models. Journal of oral and maxillofacial surgery. 1999;57(9):1040-1043.

19. Mehra P, Miner J, D'Innocenzo R, Nadershah M. Use of 3-d stereolithographic models in oral and maxillofacial surgery. Journal of maxillofacial and oral surgery. 2011;10(1):6-13.

20. Dawood A, Marti BM, Sauret-Jackson V, Darwood A. 3D printing in dentistry. British dental journal. 2015;219(11):521-529.

ATTENTION PROSPECTIVE AUTHORS

JIACD wants to publish your article!

For complete details regarding publication in JIACD, please refer to our author guidelines at the following link:

jiacd.com/author-guidelines

or email us at: editors@jicad.com

Tilted Implant Placement for Rehabilitation of Severe Atrophic Maxilla Supported by Finite Element Analysis

Dr. Venkat Ratna Nag[1] • Dr. P. Sarika[2]
Dr. Tejashree Bhagwatkar[3] • Dr. Vasantha Dhara[4]

Abstract

Background: Tilted implants have been used for rehabilitation of maxillary edentulous arches. The purpose of this article is to evaluate the clinical outcome of tilted implants where 6 implants are placed in maxilla and restored with screw retained prosthesis.

Methods: 20 patients who underwent tilted implant placement in the maxilla followed by delayed loading and 20 patients who underwent the same surgery followed by immediate loading were considered for the study. The all-tilt implant concept was supported by Finite element analysis comparing stress distribution on cortical and cancellous bone with All-on-4 concept for maxillary arch. Marginal peri-implant bone loss was calculated post 1 year and 3 year period for both the groups.

Results: The difference in the 3 year post loading marginal peri-implant bone loss between delayed and immediate loading groups was found to be insignificant using 6 tilted implants design. The FEA based von Misses stress, shows higher values for All-on-4 when compared with 6 Tilted implants design.

Conclusions: Tilted implants design when executed precisely, shows 100% survival rate in implants and prosthesis, in both the delayed and immediate loading protocols of maxillary rehabilitation.

KEY WORDS: Tilted implants, All-On-6, pterygoid dental implant, finite stress analysis

1. Reader, Department of Prosthodontics, S.B. Patil Dental College and Hospital, Bidar, Director, Institute for Dental Implantology, Hyderabad, Telangana, INDIA

2. Reader, Department of Pedodontics and Preventive Dentistry, S.B. Patil Dental College and Hospital, Bidar

3. Oral Pathologist, Institute for Dental Implantology, Hyderabad, INDIA

4. Oral and Maxillofacial Surgeon, Institute for Dental Implantology, Hyderabad, INDIA

INTRODUCTION

The early loss of maxillary posterior teeth leads to maxillary sinus pneumatization, reducing the alveolar ridge height, and thus posing challenge for implant placement.[1] Recently, dental implant supported prostheses (implant overdentures) have offered many advantages such as improved retention and support, better speech, and enhanced mastication ability when compared to the conventional methods.[2,3,4] It is considered as cheaper option but they may require more involved maintenance, thus rendering removable treatment not so economical as it may appear.[5]

The All-on-4 implant concept (Nobel Biocare, Göteborg, Sweden) was developed by Paulo Malo which includes 2 axial and 2 tilted implants. It is limited by the presence of distal cantilever that makes rehabilitation challenging without the use of more complex surgical procedure in the maxilla.[6] The tilted implant concept has been used for rehabilitation of edentulous jaws. The evolution of tilted implants has occurred as a graftless solution avoiding major anatomic structures while achieving bicortical stabilization. Numerous studies have evaluated tilted implant-prosthetic framework with decent follow up years, producing success rates of 95-100%. Configurations of All-on-4 and All-on-6 have been documented in literature with studies done on stress configuration and crestal bone loss. Babbush et al.,[7] retrospectively studied 708 implants placed at an angle in 165 patients and reported cumulative survival rate of 99.6% (99.3% in maxilla & 100% in mandible) for up to 29 months of loading. Definite prosthesis survival rate was 100%. Crespi et al.,[8] reported 98.96% of implant survival rate after three years from loading for 24 maxillary rehabilitations without any prosthetic complete failure. Rosen and Gynther[9] evaluated retrospectively the surgical outcome of tilted implants in severely resorbed edentulous maxilla as an alternative to bone grafting. They demonstrated that such patients can be treated successfully with success rate of 97% in 103 implants of 19 patients over long term follow up of 10 year (mean). Penarrocha-Oltra et al.,[10] concluded that tilted implants, both used alone or combined with axially placed implants, and rehabilitated with different prosthetic options, have high success rates, minimal complications and high patient satisfaction.

It has been highlighted that better bone implant contact and stress distribution are achieved by tilting of implants; and by using 6 implants concept, stabilization and elimination of cantilever is possible. In this study, 6 tilted implants were placed subcrestally (length of 16mm-25mm) (30-45° angulation) in anterior and posterior regions of maxilla with nasal cortex engagement and pterygoid pillar engagement respectively. The implants were placed flapless. Implants were immediately loaded (IL) within 48 hours in most of the cases where good primary stability was achieved.[11,12] In the other cases, the delayed protocol was followed (3 months) for remodeling of bone around implant and Osseo integration.[2,13,14]

The aim of this study was to compare the clinical outcome of 6 tilted implants between two groups: Delayed (Group A) and Immediate (Group B) loading. The null hypothesis of this study was that there is no difference in the outcome between the two protocols using this technique. This study was also supported by a finite element analysis for better understanding the stress on cortical and cancellous bone in 6 tilted implant design concept when compared to All-on-4 concept for maxillary arch.

Figure 1a: Pre-surgical radiograph of Case 1.

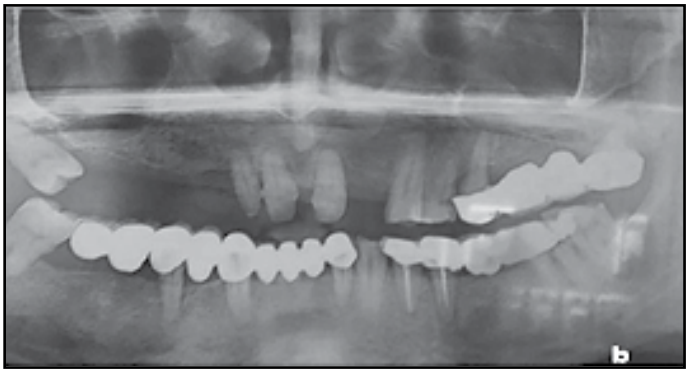

Figure 1b: Pre-surgical radiograph of Case 2.

Figure 1c: Pre-surgical radiograph of Case 3.

Figure 1d: Pre-surgical radiograph of Case 4.

MATERIALS AND METHODS

Patients were selected between age groups of 35-80 years, with good general health and no contraindications to any surgical procedure who underwent 6 tilted implants placement for edentulous maxilla. Exclusion criteria for the study were patients unable to commit for 4 years follow-up. Informed consent was taken from all the patients after they agreed for the treatment and follow up protocol of the study. Implant placement with 4 year follow up was performed at Institute for Dental Implantology, Hyderabad, INDIA, from April 2013 to October 2018. The implants used were Bioline-i Implants (Bioline Dental GmbH & Co. KG- Germany). All patients were subjected to standard pre-surgical workup of panoramic radiograph and computed tomography for the assessment of vital structure and bone density after which they underwent tilted implant placement in the maxilla. Patients were then divided into two groups, Group 1 (patients in whom primary stability of 40Ncm was achieved on implant placement) and Group 2 (primary stability of 65Ncm) as per the respective delayed and immediate protocol (Figures 1a-1d).

SURGICAL PROTOCOL

A metal surgical guide was used to shows the angulation of drills required at the planned six surgical sites of implants placement (Canine, second premolar, first/second molar). Radiographic assessment to visualize the direction of the drill into the bone and its relation to the anatomic



Figure 2: Model showing All-on-4 concept.

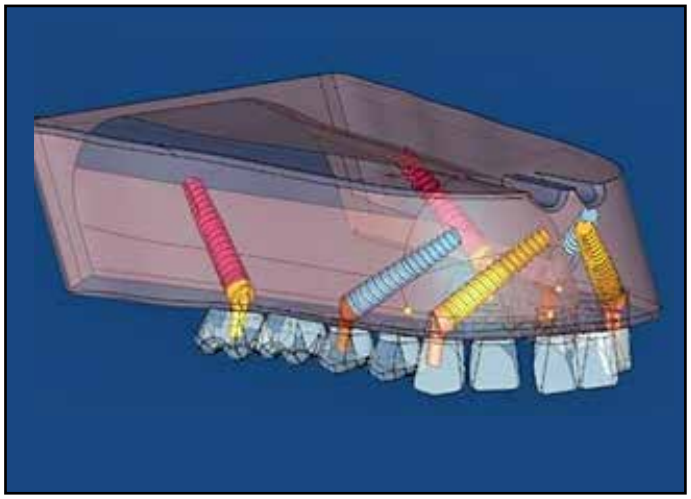

Figure 3: Model showing the 6 tilted implant concept.

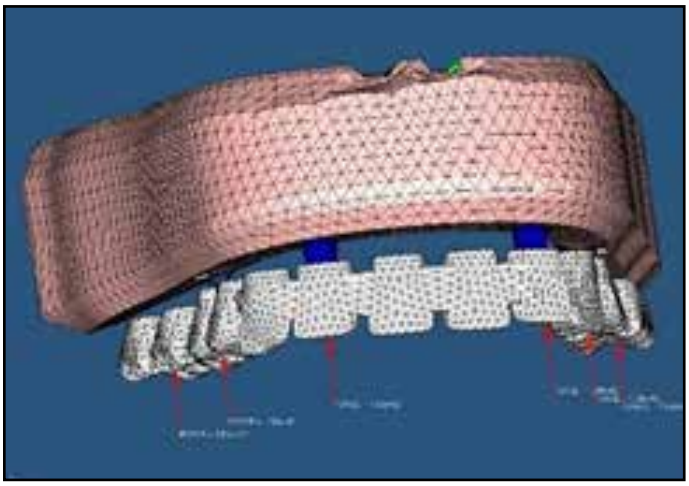

Figure 4a: All-on-4 implant concept of load application (red lines). Rigid fixation restriction in the upper maxilla (green lines).

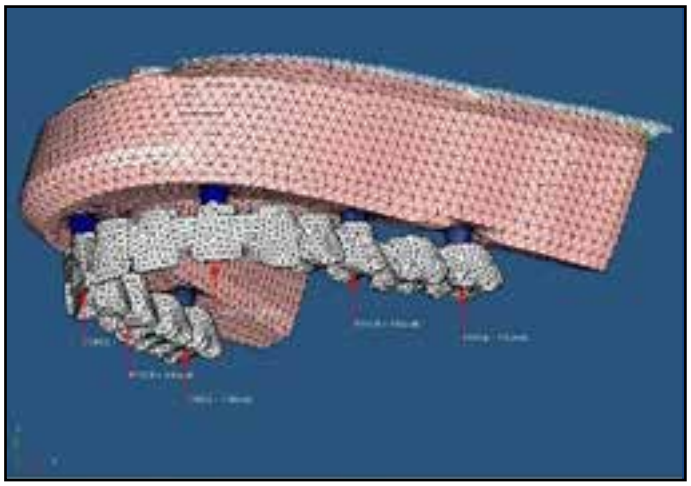

Figure 4b: 6 tilted implant concept of load application (red lines). Rigid fixation restriction in the upper maxilla (green lines).

structures was done intraoperatively (i.e ahead of the anterior wall of maxillary sinus and beyond the posterior wall of maxillary sinus with adequate Anterior-Posterior space). A depth gauge was used to finalize the length of the implant by nasal cortical proprioception confirmed with RadioVisioGraphy. The selected implant was placed following the concept of osseodentification. The primary stability of the implant was then checked with the torque test to determine the loading protocol. Thus, 2 tilted implants were placed in the premaxilla engaging the alveolar and nasal cortex and 1 pterygoid implant in the posterior maxilla (Bicortical engagement). The same procedure of placement of the three implants were done on the other side. All the six implants were placed subcrestally in a flapless manner.[15] Implants were torqued and the values

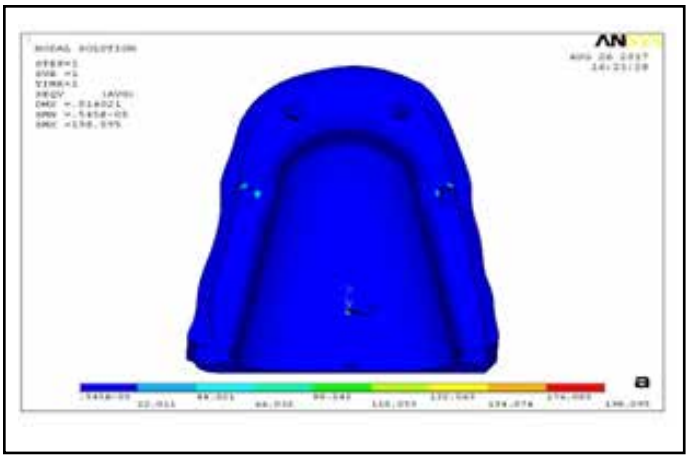

Figure 5a: All-on-4 finite stress analysis in cortical bone.

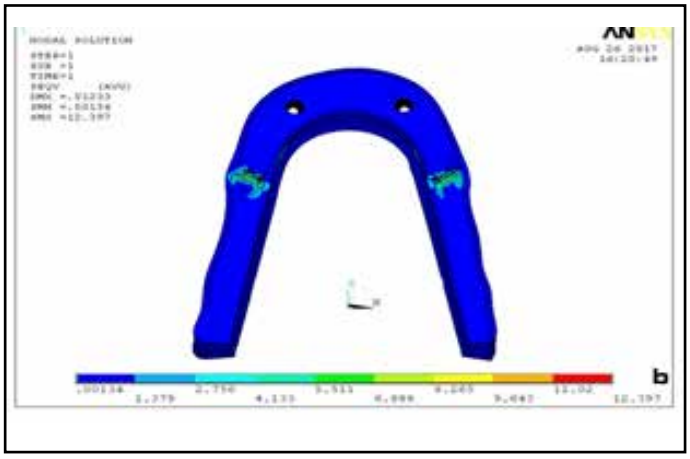

Figure 5b: All-on-4 finite stress analysis in cancellous bone.

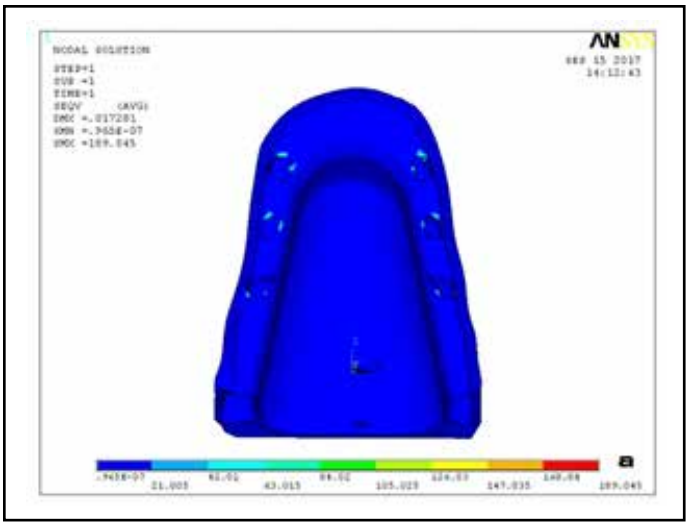

Figure 6a: 6 tilted implants in cortical bone.

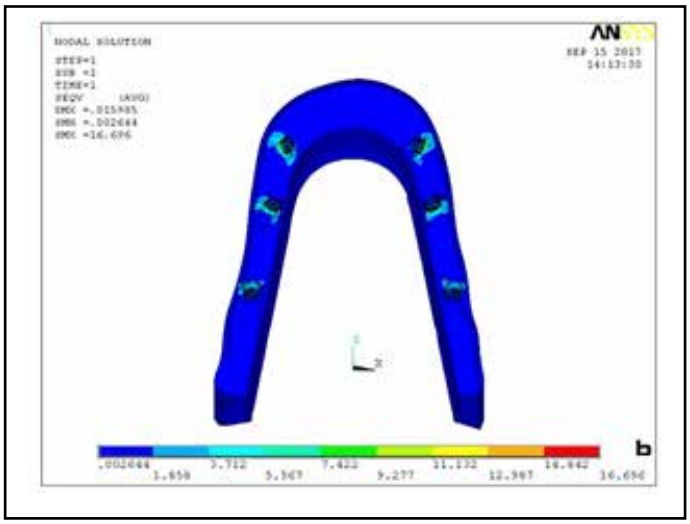

Figure 6b: Tilted implants in cancellous bone.

were recorded to categorized the patients for loading protocol. Standard Postoperative care was advised for patients. Group A patients was asked to report for follow up after a week's time.

PROSTHETIC PROTOCOL

After surgical intervention on the same day of surgery, multi-units were placed (30/40/50° etc.) to compensate the angulation of tilted implants. For patients under Group A, Alginate impressions were taken and bite was recorded in centric relation. Immediate provisionalization was done with self-cure acrylic and cemented with provisional cement (IRM). A definitive prosthesis was planned after 3–4 months.

For the group B patients, final prosthetic rehabilitation procedures were started immediately after implant placement. The phase of

Table 1: Stress distribution on Peri-implant bone by various concepts.				
	Stress By Implants			
	Cortical Bone		Cancellous Bone	
	Max (Mpa)	Min (Mpa)	Max (MPa)	Min (MPa)
All-on-4	**198.572**	**22.011**	**17.397**	**1.8502**
Tilted Implants	**76.048**	**12.204**	**12.073**	**0858**

impression taking with transfer copings, Jig trial, metal framework trial followed by placement of final prosthesis using CAD-CAM technology for design and fabrication of screw retained permanent prosthesis was done within 2-5 days.

After 1 year of definitive prostheses loading in both the groups, the patients were recalled and prostheses removed, and checked for implant stability. Periapical radiographs and panoramic x-rays were taken to check for the crestal bone loss. Occlusion was checked. These patients were recalled up to 3 years and above mentioned observational protocol was followed for routine evaluation at every visit.

FINITE ELEMENT ANALYSIS

In a parallel study, three-dimensional finite element models of maxilla with tilted implants were used to investigate the amount and distribution of stress in maxilla both cortical and cancellous bone. The 3D model of maxilla was developed from the computerized tomography (CT) data of a patient. In the maxillary model six implants with diameter of 3.75 mm and 18 mm length were placed with two tilted implants being modelled at the canine, two at the second premolar position and two implant at the first/second molar position i.e pterygoid implant (Figures 2,3). CAD images of implants and prosthetic components were supplied by the manufacturer (Bioline dental GmbH & Co. KG Akazien str.[7] 16356 Germany).Another pair of similar models were made with four implants in the maxillary arch to simulate the All-on-4 concept of implant placement. Boundary conditions were fixed, by constraining the movement of the peripheral nodes and the properties were given to the designed models to simulate the clinical situation (Figures 4a,b). In total, 2 models were made for the "Tilted implants (6 in number)" and "All-on-4"

IMPLANT SURVIVAL CRITERIA

The survival of the implant was based on the implant stability, absence of pain and infection, radiographic analysis in the 1styear and 3rdyear follow up. No implant failure was noted during the follow up. Peri-implant bone level was evaluated for the 1st year and 3rd year using the orthopantomograph. A line was traced

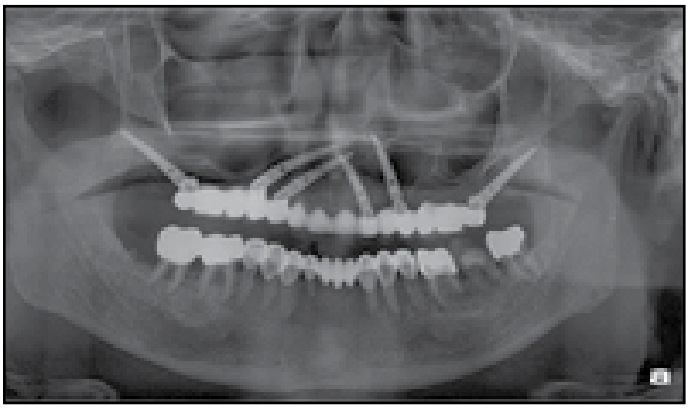

Figure 7a: Radiograph of treated patient immediately after surgery.

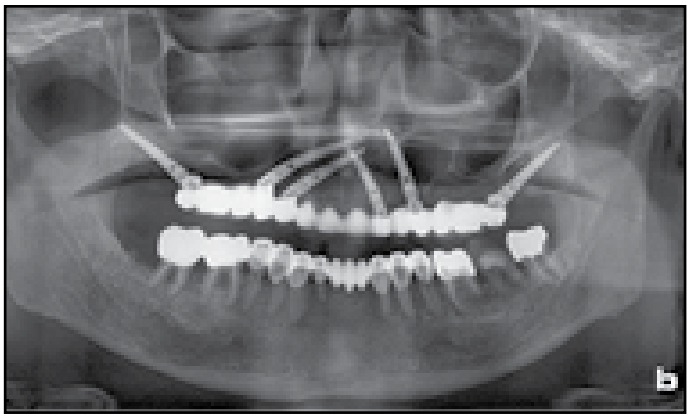

Figure 7b: Radiograph of treated patient 1 year after surgery.

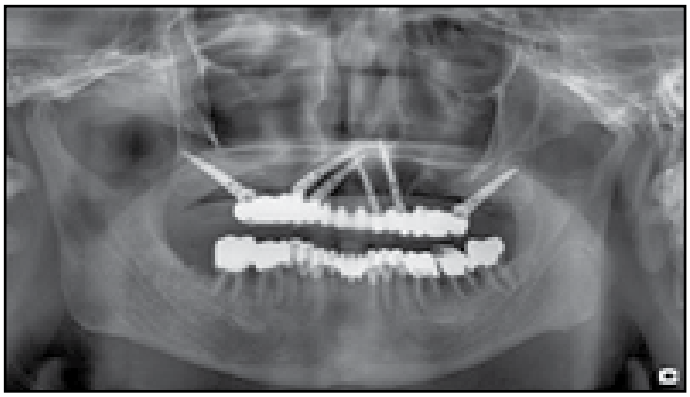

Figure 7c: Radiograph of treated patient 3 years after surgery.

from the implant/ prosthetic restoration junction to the bone crest on the mesial and distal sides of each implant which was measured using the Image J software. The mean bone loss values were recorded from each radiograph.[16]

RESULTS

Modelling with Numerical analysis

The results of the numerical analysis were as follows: the maximum von Mises stress recorded in the All-on-4 model were 198.572Mpa and 17.397Mpa for cortical and cancellous bone respectively (Figures 5a,b), whereas the maximum stress recorded in the "6 Tilted implants" model was 76.048Mpa and 12.073Mpa for cortical and cancellous bone respectively (Figures 6a,b) (Table 1).

CLINICAL FOLLOW UP

All the 40 patients showed for follow up. Out of 40 patients, a few patients showed mucositis which was treated. Another complication noted was chipping of the ceramic layering in both the groups, which occurred after 2 years of follow-up. In this case the prostheses were removed and a new prosthesis given.

MARGINAL BONE LOSS

Peri-implant bone loss data for 1st year and 3rd year in both the groups were compared (Figures 7a-10c). There was no statistically significant difference of marginal bone levels in the 1 year follow up (p=0.428) (Table 2 and Graph 1) and 3 year follow up (p=0.195) (Table 3 and Graph 2) periods for both the groups.

DISCUSSION

The "All-on-4" concept provides rehabilitation of a fully edentulous jaw which has minimal

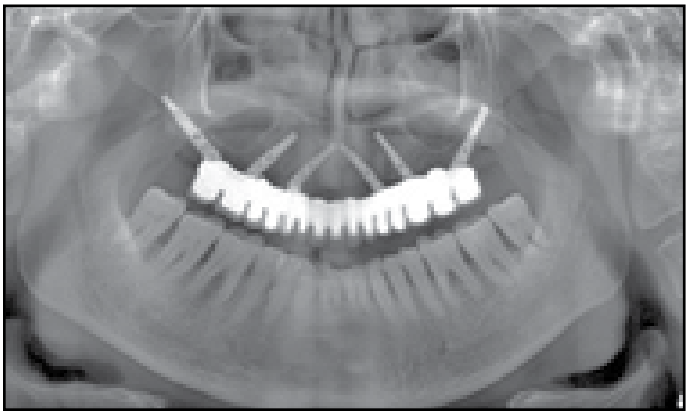

Figure 8a: Radiograph of treated patient immediately after surgery.

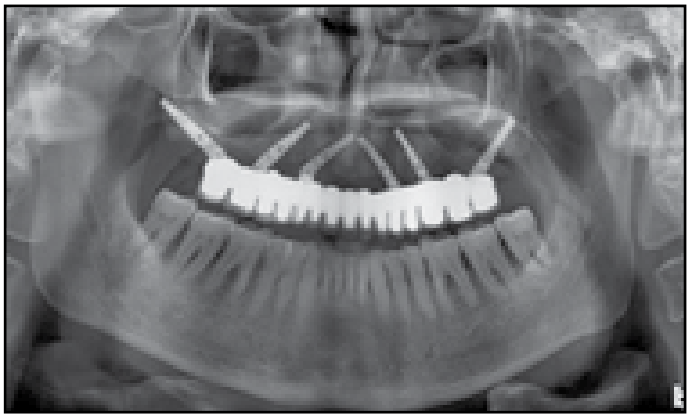

Figure 8b: Radiograph of treated patient 1 year after surgery.

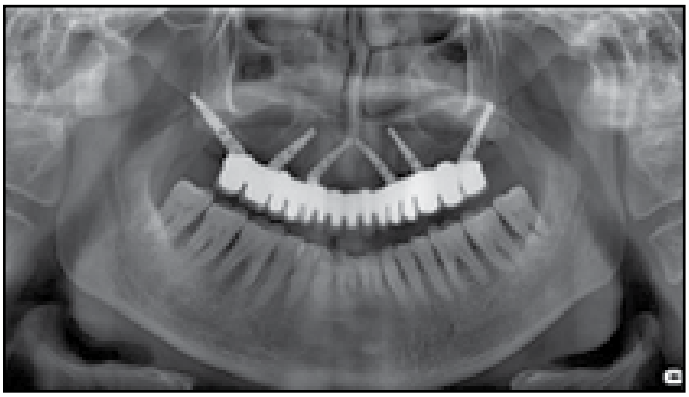

Figure 8c: Radiograph of treated patient 3 years after surgery.

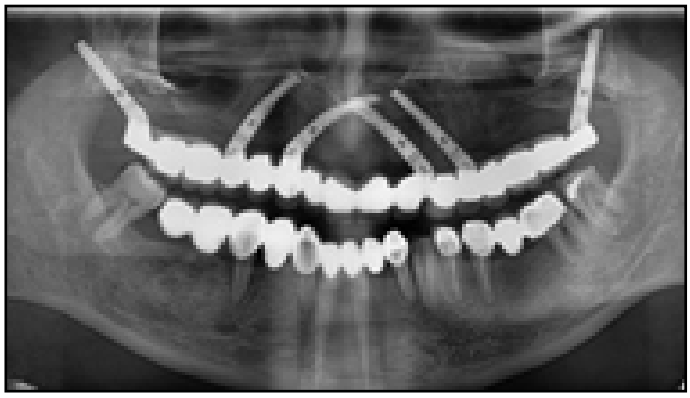

Figure 9a: Radiograph of treated patient immediately after surgery.

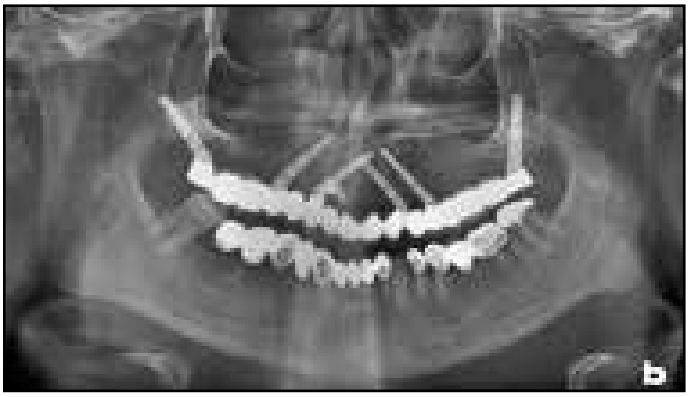

Figure 9b: Radiograph of treated patient 1 year after surgery.

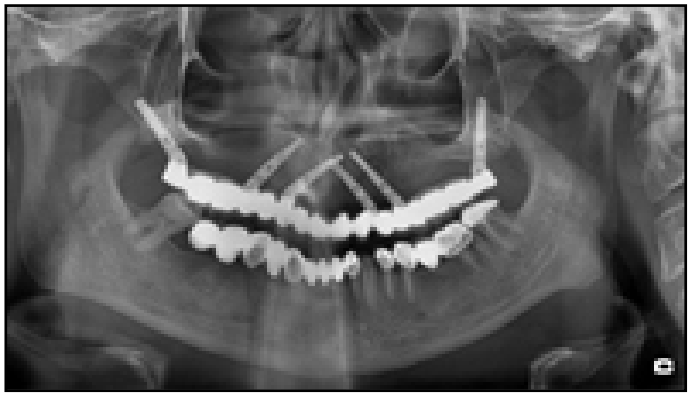

Figure 9c: Radiograph of treated patient 3 years after surgery.

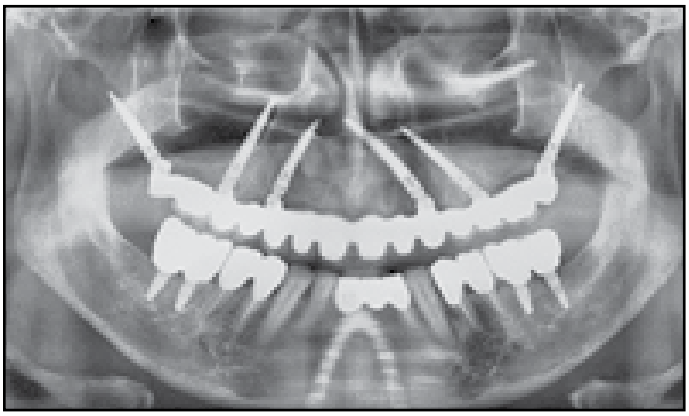

Figure 10a: Radiograph of treated patient immediately after surgery.

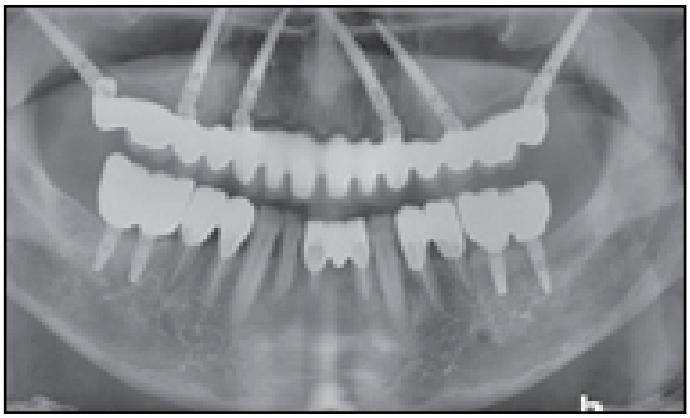

Figure 10b: Radiograph of treated patient 1 year after surgery.

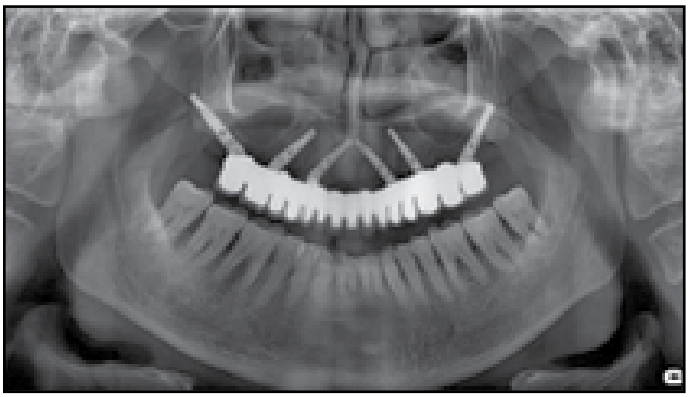

Figure 10c: Radiograph of treated patient 3 years after surgery.

bone volume. Although the procedure requires short treatment intervals, low cost, it has certain mechanical limitations.[17,18] In the Tilted implants concept, 6 tilted implants were placed with bicortical engagement and sufficient A-P spread.

Screw retained prosthetic solutions with cross arch stabilization were provided. This design has been suggested to be the most predictable restorative option for immediate loading.[19,20] Generally when torque values of more than 50Ncm are achieved, immediate loading is possible. The 6 tilted implants design avoids vital anatomic structures, maintains marginal bone levels, minimizes need for grafting procedures, and eliminates distal cantilevers with greater distribution of implant connections thus providing bio-mechanical advantage. The finite analysis concluded that the load dissipated on cortical and cancellous bone was less than All-on-4. Immediate loading requires minimal torque values of 35–40 Ncm without rotation. This prerequisite when combined with a carefully designed cross-arch-stabilized interim hybrid prosthesis with minimal cantilevers will provide the greatest chance for success with tilted implants.[21-24] Thus broad distribution of tilted implants will be beneficial from both a biomechanical and restorative standpoint.

Malo et al.[25] performed a study on tilted implants with 20 to 25 mm of length with bicortical anchorage for prosthetic rehabilitation of complete edentulous jaws. In their study, none of the implants failed rendering a cumulative implant survival rate of 100% along with low marginal bone remodeling and low incidence of complications.

Cavalli et al.[26] carried out a study to assess the treatment outcome of both tilted and axially placed implants in the edentulous maxilla. The study reported no implant failures were

Table 2: One-year follow-up mean values of the radiographic peri-implant marginal bone levels in immediate and delayed groups.		
Groups	n	Mean (SD)
Delayed	20	0.1810 (0.0296)
Immediate	20	0.1898 (0.0388)
t value		0.801
p value		0.428 (NS)
Independent t test; NS-Non-significant		

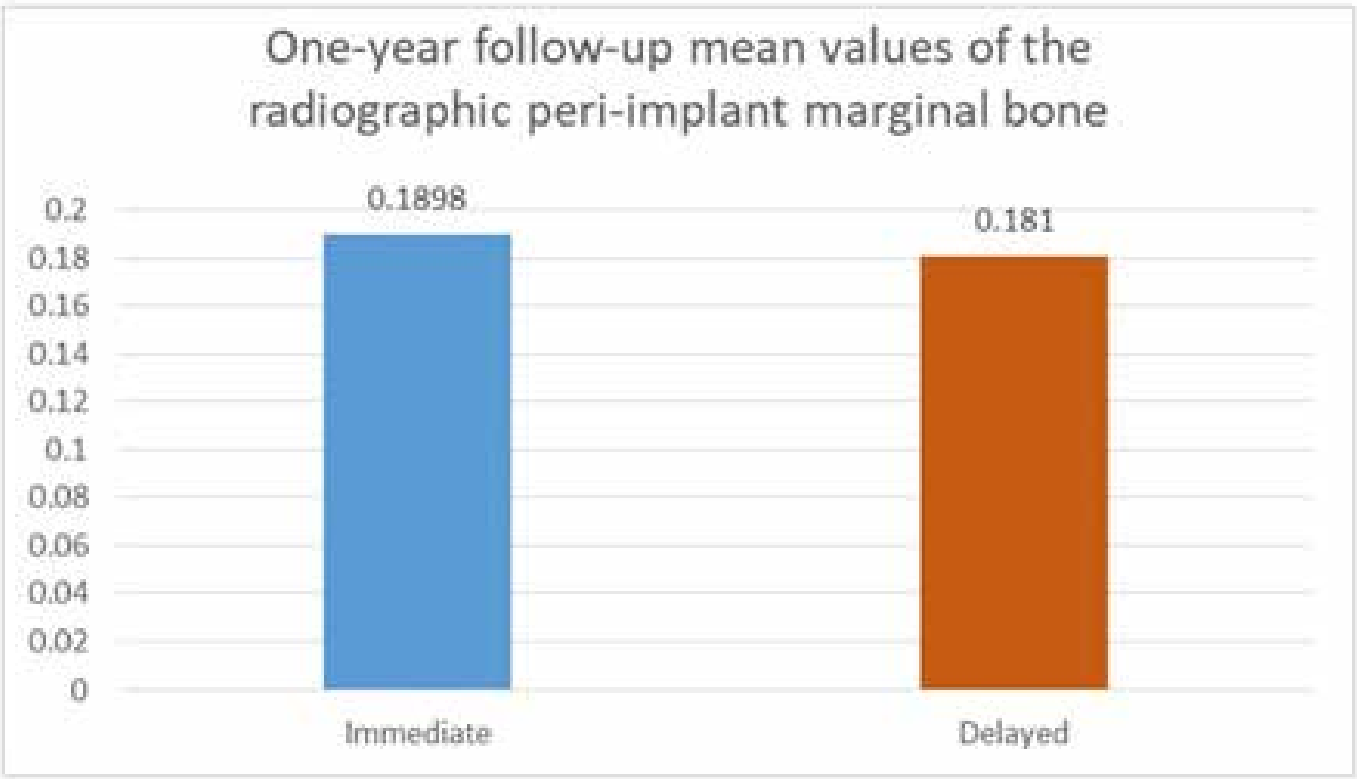

Graph 1: Showing one-year follow-up mean values of radiographic marginal bone levels

Table 3: Three-year follow-up mean values of the radiographic peri-implant marginal bone levels in immediate and delayed groups.

Groups	n	Mean (SD)
Delayed	20	0.1903 (0.0313)
Immediate	20	0.2038 (0.0334)
t value		1.320
p value		0.195 (NS)

Independent t test; NS-Non-significant

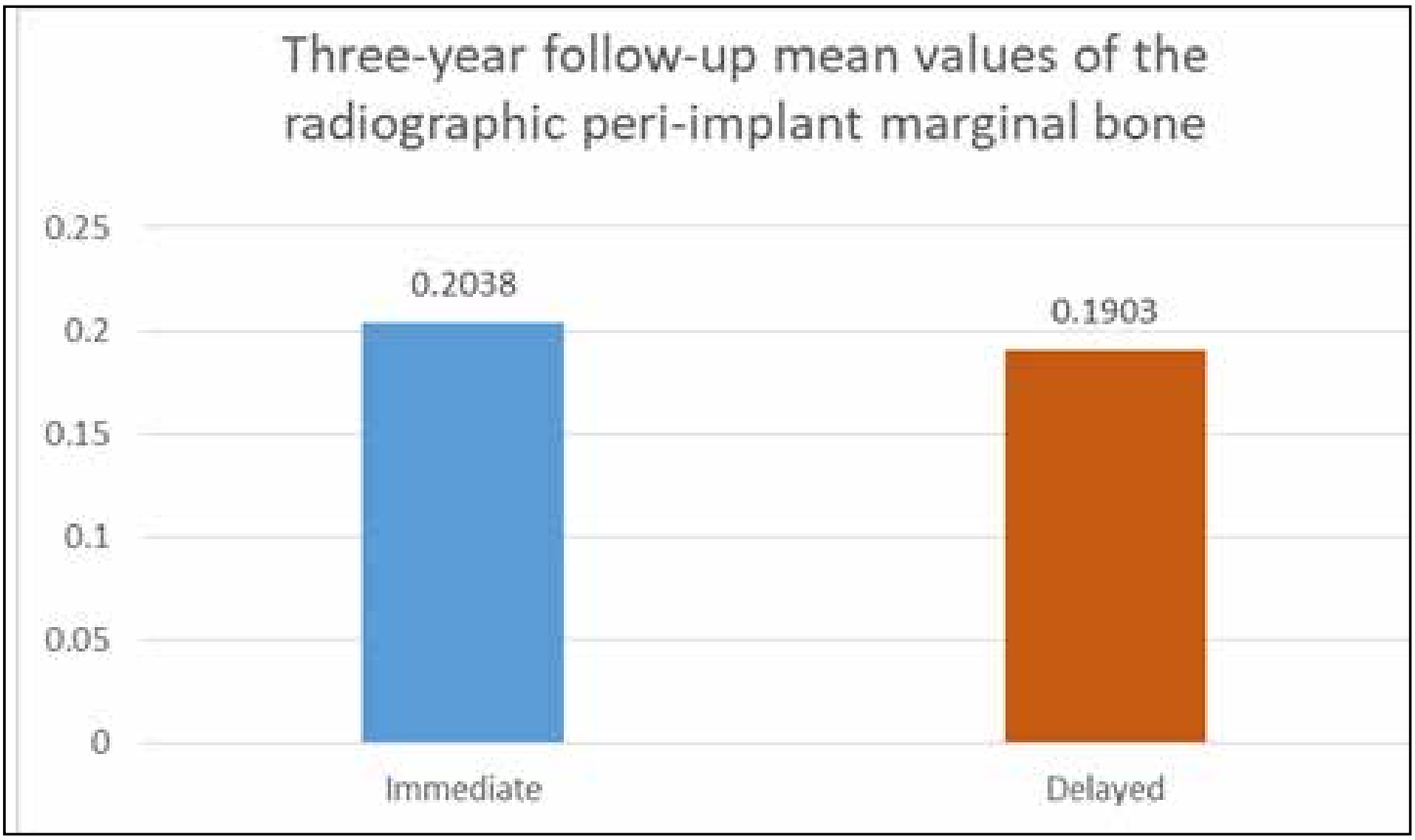

Graph 2: Showing three-year follow-up mean values of radiographic marginal bone levels

recorded in immediate loading, leading to a cumulative implant survival rate of 100% and could be considered a viable treatment option.

Curi et al.[16] performed a retrospective study for implant and prosthesis survival rates of pterygoid implants with delayed loading found overall pterygoid survival rate is 99% and prosthesis survival rate was 97.7%. Also concluded placement of implants in pterygoid region is alternative treatment modality.

Toljanic et al.[27] retrospectively compared long-term outcomes for immediately loaded tilted and axial implants placed in the posterior maxilla and concluded that predictable long term implant rehabilitation can be achieved for immediate loading.

Menini et al.[28] performed a meta-analysis study to evaluate the outcome of straight and tilted implants for rehabilitation of edentulous maxilla after at least 1 year of function. Tilted implants demonstrated a favorable prognosis in full-arch immediate loading rehabilitations of the maxillae.

One of the limitations of the present study is that the number of patients included is less to detect statistically significant differences in prostheses/implant failures. The follow-up of 3 years could be a shorter time to predict the long-term outcome of "Tilted implants" concept. To improve the more reliability of this concept, more long term studies are to be performed and proposed by experienced dentists in their practice. Even though, the results of immediate loading and delayed loading are not significantly different, implant placement protocol varies with primary stability achieved.

CONCLUSION

In the current study, the tilted implant (with 6 implants) concept of full mouth restoration in delayed loading and immediate protocol showed 100% survival rate, supported by a very minimal cortical and cancellous bone loss using finite element analysis. "Tilted implants" thus is proven to be a clinically effective treatment option in severe atrophic maxilla if planned accurately, bypassing few complicated and expensive bone augmentation procedures, sinus lifts which would be otherwise indicated.

Correspondence:
Dr. Venkat Ratna Nag
Director, Institute for Dental Implantology
8-2-598/A/1, GB,
Uma Devraj Villa, Road no. 10,
Banjara hills, Hyderabad- 500034

Disclosure:
The authors report no conflicts of interest with anything mentioned within this article.

References

1. Malo P, Nobre MDA, Lopes A, Moss SM, Molina GJ. A longitudinal study of the survival of Al-on-4 implants in the mandible with up to 10 years of follow-up. J Am Dent Assoc. 2011;142(3):310–320.

2. Nag PVR, Sarika P, Khan R et al. Tall and tilted pin hole immediately loaded implants (TTPHIL) technique for maxillary arch rehabilitation. International Journal of Research and Review. 2018; 5(6):104-110.

3. Thomason JM, Feine J, Exley C. Mandibular two implant-supported overdentures as the first choice standard of care for edentulous patients. Br Dent J 2009 Aug 22;207(4):185-186.

4. Singh AV, Singh S, Rojo AV. Quality life for elderly edentulous patients with implant over dentures, implantology section. Dental Practice 2013 May-June;11(6):22-25.

5. Duyck J, Van Oosterwyck H, Vander Sloten J, De Cooman M, Puers R, Naert I. Magnitude and distribution of occlusal forces on oral implants supporting fixed prostheses: an in vivo study. Clin Oral Implants Res. 2000;11(5):465–475.

6. Malo P, Rangert B, Nobre M. All-on-four immediate function concept with branemark system implants for completely edentulous mandibles: a retrospective clinical study. Clin Implant Dent Relat Res. 2003;5(suppl 1):2–9.

7. Babbush CA, Kutsko GT, Brokloff J. The All-on-Four Immediate Function Treatment Concept With nobelactive Implants: A Retrospective Study. Journal of Oral Implantology. 2011;37(4):431-45.

8. Crespi R, Vinci R, Capparé P, Romanos GE, Gherlone E. A clinical study of edentulous patients rehabilitated according to the "all on four" immediate function protocol. The International Journal of Oral & Maxillofacial Implants. 2012;27(2):428–34.

9. Rosen A, Gynther G. Implant Treatment Without Bone Grafting in Edentulous Severely Resorbed Maxillas: A Long-Term Follow-Up Study. Journal of Oral and Maxillofacial Surgery.2007;65(5):1010-16.

10. D. Penarrocha-Oltra, E. Candel-Marti, J. Ata-Ali, and M. Penarrocha, "Rehabilitation of the atrophic maxilla with tilted implants: review of the literature," The Journal of Oral Implantology. 2013 Oct;39(5):625-32.

11. Georgios R, Stuart F, Cyril H, Sang C, Dennis T. Survival Rate of Immediately vs Delayed Loaded Implants: Analysis of the Current Literature. Journal of Oral Implantology 2010;36(4):315-324.

12. Nag V, Sarika, Addanki P, Bhagwatkar T. Bite reconstruction in aesthetic zone using TTPHIL technique. Natl J Integr Res Med 2018; 9(5):51-52.

13. Venkat Nag, P., Sarika, P., Pavankumar, A. (2017). TTPHIL-ALL TILTTM Concept – An Innovative Technique in Immediate Functional Loading Implant Placement in Maxilla. Scholars Journal of Dental Sciences. 4(9),397-399.

14. Venkat Nag, P., Sarika, P., Khan, R., &Bhagwatkar, T. (2018). Immediate implantation and loading in just two days with TTPHIL technique using CAD/CAM Prosthesis. International Journal of Applied Dental Sciences, 4(3): 209-213.

15. Sotto-Maior BS, Lima CA, Senna PM, Camargos GV, Del Bel Cury AA. Biomechanical evaluation of subcrestal dental implants with different bone anchorages. Braz Oral Res.,(São Paulo) 2014;28(1):1-7.

16. Curi et al. Retrospective study of Pterygoid implants in the Atrophic Posterior Maxilla: Implant and Prosthesis Survival rate up to 3 years. The Int J of Oral and Maxillofacial Implants 2015; 30:2: 378-82.

17. S.B. Patzelt, O. Bahat, M.A. Reynolds, J.R. Strub. The All-on-Four Treatment Concept: A Systematic Review.Clin. Implant. Dent. Relat. Res. 2014;16:836–855.

18. G. Heydecke, M. Zwahlen, A. Nicol, D. Nisand, M. Payer, F. Renouard, P. Grohmann, S. Muhlemann, T. Joda.What is the optimal number of implants for fixed reconstructions: a systematic review. Clin. Oral Implants Res. 2012;23: 217–228.

19. Millen C, Brägger U, Wittneben JG. Influence of prosthesis type and retention mechanism on complications with fixed implant-supported prostheses: a systematic review applying multivariate analyses. Int J Oral Maxillofac Implants. 2015;30(1):110–24.

20. Wittneben JG, Millen C, Brägger U. Clinical performance of screw- versus cement-retained fixed implant-supported reconstructions–a systematic review. Int J Oral Maxillofac Implants.2014;29(Suppl):84–98.

21. M, Grusovin MG, Willings M, Coulthard P, Worthington HV. The effectiveness of immediate, early, and conventional loading of dental implants: a Cochrane systematic review of randomized controlled clinical trials. Int J Oral Maxillofac Implants. 2007;22:893–904.

22. Szmukler-Moncler S, Salama H, Reingewirtz Y, Dubruille JH. Timing of loading and effect of micromotion on bone-dental implant interface: review of experimental literature. J BiomedMater Res. 1998;43:192–203.

23. Ottoni JM, Oliveira ZF, Mansini R, Cabral AM. Correlation between placement torque and survival of single-tooth implants. Int J Oral Maxillofac Implants. 2005;20:769–76.

24. Ghoul WE, Chidiac JJ. Prosthetic requirements for immediate implant loading: a review. J Prosthodont. 2012;21(2):141–54.

25. Paulo Maló, M de A Nobre, A Lopes; R Rodrigues. Preliminary Report on the Outcome of Tilted Implants with Longer Lengths (20–25 mm) in Low-Density Bone: One-Year Follow-Up of a Prospective Cohort Study. Clin Implant Dent Relat Res. 2015 Jan;17Suppl 1:e134-42.

26. N Cavalli, B Barbaro, D Spasari, F Azzola, ACiatti, and L Francetti. Tilted Implants for Full-Arch Rehabilitations in Completely Edentulous Maxilla: A Retrospective Study. International Journal of Dentistry, Volume 2012, Article ID 180379.

27. Toljanic J, Ekstrand K, Baer R, Thor A. Immediate loading of tilted and axial posterior implants in the Edentulous Maxillary arch: A Retrospective comparison of 5 year outcomes. Int J Oral Maxillofac Implants 2018;33:433-438.

28. M. Menini, A. Signori, T. Tealdo, M. Bevilacqua, F. Pera, G. Ravera and P. Pera. Tilted Implants in the Immediate Loading Rehabilitation of the Maxilla: A Systematic Review J DENT RES 2012 91: 821.

THE ONLY

"ONE Drill
ONE Abutment
ONE Kit"

Dental Implant System

OsseoFuse

1drill Implant

Call now to learn more

888.446.9995

www.osseofuse.com

support@osseofuse.com

A Novel Procedure of Regaining Aesthetics with Implants and Autogenous Dentin Graft: A Report of Three Cases with One Year of Follow Up

Dr. Verma Kamal[1] • Dr. Viswambaran[2]
Dr. Yadav Rajesh Kumar[2] • Dr. Verma Rashima[3]

Abstract

Generally, extracted teeth have been discarded as infective medical dusts in the world. While human bone autograft was done in 19th century, human dentin autograft for bone augmentation was reported in 2003. Dentin matrix like bone has the inborn chemical and physical properties to attract progenitor cells and induce them to generate new bone. Both decalcified bone and decalcified dentin are composed of predominantly type I collagen (95%) and the remaining as non-collagenous proteins including small amount of growth factors. The coagulation action of blood plasma by both decalcified bone and dentin are advantageous during surgical procedures.

This series of clinical cases describes a novel procedure of prosthodontic management of the fractured maxillary central incisors using two stage implants reinforced with autogenous dentin graft obtained by immediate transformation of extracted teeth. Results demonstrated that autogenous dentin could be recycled as an innovative biomaterial for local bone engineering.

KEY WORDS: Atraumatic extraction, Smart dentin grinder, autogenous particulate dentin graft, osseointegration, implants

1. Graded specialist, Division of Prosthodontics, MDC Kirkee East
2. Senior specialist, Division of Prosthodontics, ADCR&R
3. Dental surgeon, ECHS

Figure 1a: Intraoral frontal view in occlusion.

Figure 1b: IOPA showing fractured maxillary central incisors.

Figure 2: Atraumatic extraction of maxillary central incisors.

INTRODUCTION

Bone grafts (autogenous, allogenic, xenogeneic and alloplastic materials) have been used for regeneration of dentoalveolar defects for quite some time. While human bone autograft was first used in the 19th century, human dentin autograft for bone augmentation was first reported in 2003.[1] In 2009, Korea Tooth Bank was established in Seoul for the processing of the tooth-derived materials, and an innovative medical service was begun for bone regeneration. Recently, tooth-derived materials have become a realistic alternative to bone grafting and have been a huge success with clinicians and patients owing to the excellent osteoconductive and osteoinductive properties of the graft and an almost nonexistent host tissue reaction. Dentin matrix, like bone, has the inborn chemical and physical properties to attract progenitor cells and induce them to generate new bone. At least 90% of organic content of dentin is type I collagen, which plays an important role in bone formation and mineralization.[2,3] The coagulation action of blood plasma by both decalcified bone and dentin are advantageous during surgical procedures.[4,5]

This clinical case series describes a novel procedure of prosthodontic management of the fractured maxillary central incisors using two stage implants reinforced with autogenous dentin graft obtained by immediate transformation of extracted teeth. Three patients were treated by similar procedures. The patients

Figure 3a: Smart Dentin Grinder.

Figure 3b: Milling of teeth.

were reevaluated for implant survival and prosthesis success after a period of one year.

CASE 1

A 21 year old patient reported to our Dental Centre with chief complaints of pain and mobility in upper front teeth since last ten months post trauma. The patient was a nonsmoker with good oral hygiene and had no remarkable medical history. Clinical examination revealed grade III mobile maxillary central incisors (Figure 1a). Radiological examination showed a fracture of maxillary central incisors at the apical third of the roots (Figure 1b). After consulting an endodontist, a treatment plan was formulated which included atraumatic extraction of maxillary central incisors, preparation of autogenous dentin graft for bone augmentation, two stage implant placement and functional rehabilitation with fixed prosthesis.

PROCEDURE

Maxillary and mandibular diagnostic impressions were made with irreversible hydrocolloid (Plastalgin, Septodont, France) and poured in dental stone (Kalstone, Kalabhai, India). The casts were articulated and diagnostic wax up was done to

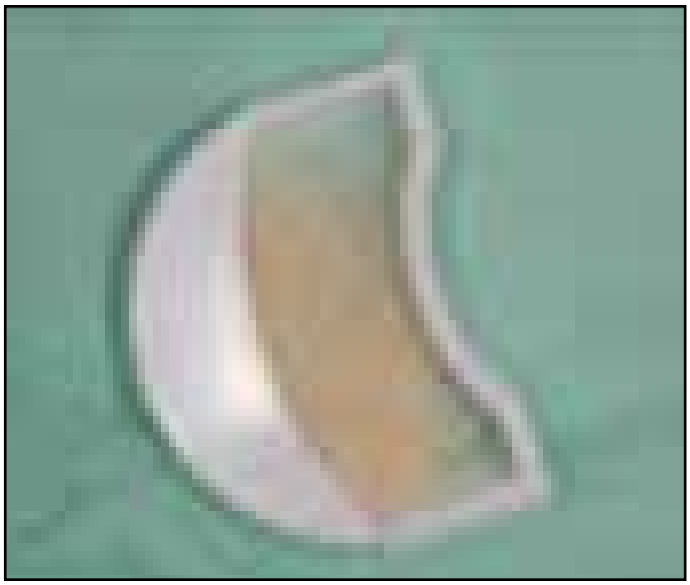

Figure 3c: Drawer that collects particulate dentin.

Figure 3d: The particulate dentin graft.

rehearse a proposed restorative plan and explain the intended procedure to the patient. Informed consent was taken from the patient and the maxillary central incisors were atraumatically extracted (Figure 2). Immediately after extraction, the periodontal ligament, enamel and cementum of the extracted teeth were removed with a tungsten bur. The teeth were rinsed with distilled water and were subjected to milling in a smart dentin grinder (Kometa Bio) (Figures 3a-d). The grinder takes 3-4 seconds to grind the dentin. A vibrating movement of the grinding chamber for 20 seconds lets the particles of less than 1200μm fall through a sieve to a lower chamber. The particles less than 300 μm fall into a waste drawer as their dimensions are non-efficient for bone grafting. The particulate matter in the range of 300 to 1200 μm hence retrieved was treated with a dentin cleanser (0.5M of NaOH and 30% alcohol) for ten minutes in a sterile glass container which dissolves most of the organic debris, bacteria and toxins but does not harm the dentin collagen. The particulate matter was then rinsed for one minute in phosphate buffered saline which adds phosphates which is important for bio-activeness. The wet particulate was placed on a hot plate (140o^{C}) for five minutes and the dry bacteria free autologous dentin graft was obtained. The process from tooth extraction upto grafting takes approximately 15-20 minutes.

Two 3.8 mm x 13mm two stage implants (Equinox, Myriad Plus) were placed in accordance with the standard implant surgical protocols in the extraction sockets of maxillary central incisors (Figure 4a), primary stability was achieved by wrenching the implant into the bone beyond the apex of the socket and the autogenous dentin graft was compacted in the space around the implants (Figure 4b). Interrupted non resorbable 3-0 silk sutures were placed to achieve primary closure. Post-operative instructions were given to the patient and sutures were removed after one week. A second stage surgery was performed after four months. The angulated abutments were screwed and the implant stability was measured

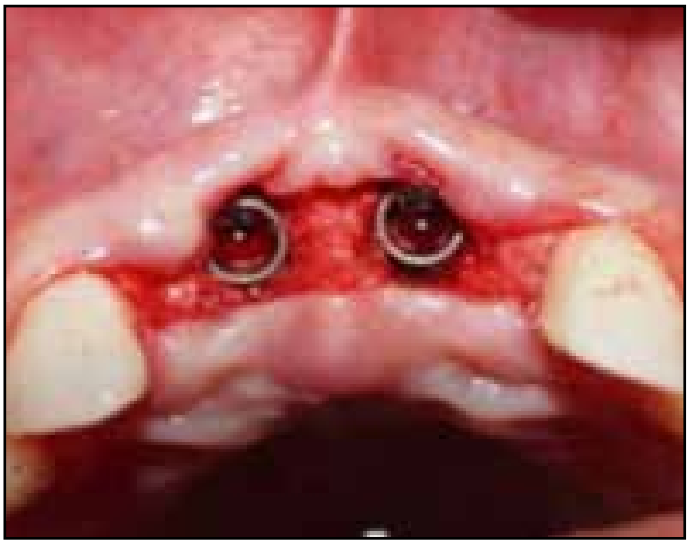

Figure 4a: Placement of two 3.8mm x 13mm implants and autogenous dentin graft in fresh extraction sockets.

Figure 4b: Placement of two 3.8mm x 13mm implants and autogenous dentin graft in fresh extraction sockets.

by using Periotest (Ostell Mentor, Goteborg, Sweden). Pleasing smile was achieved by porcelain fused to metal crowns in relation to 11 and 21 (Figures 5a,b). The patient was functionally and aesthetically satisfied with the implant fixed prosthesis. A one year follow up showed good esthetics, osseointegration and maintenance of bone around the implants (Figures 6a,b).

CASE 2

A 25 year old male patient reported with chief complaints of missing front upper teeth 6 months post trauma. The patient had good oral hygiene and no relevant medical history. Radiological examination revealed retained apical half roots segments of both the maxillary central incisors which were atraumatically extracted and used as a dentin graft. The rest of the procedure was similar to that of Case 1.

CASE 3

A 30 year old patient reported with chief complaints of fractured upper front teeth 6 months post trauma. Clinical examination revealed fractured maxillary central incisors below the level of cementoenamel junction. The roots were atraumatically extracted and the routine procedures of dentin graft and implant placement were followed.

DISCUSSION

Autogenous dentin graft is an innovative material owing to its very similar physical and chemical components when compared to bone. Both tooth and alveolar bone are derived from neural crest cells and are made up of the same Type I collagen. Furthermore, dentin contains BMPs, which induce bone formation and non-collagenous proteins such as osteocalcin, osteonectin, and dentin phosphoprotein.[6] Autogenous bone graft is ideal for the reconstruction of hard tissue defects as it has osteoconductive, osteoinductive and osseointegrative capacities. It does not trigger a foreign



Figure 5a: IOPA showing implants immediately after surgery.

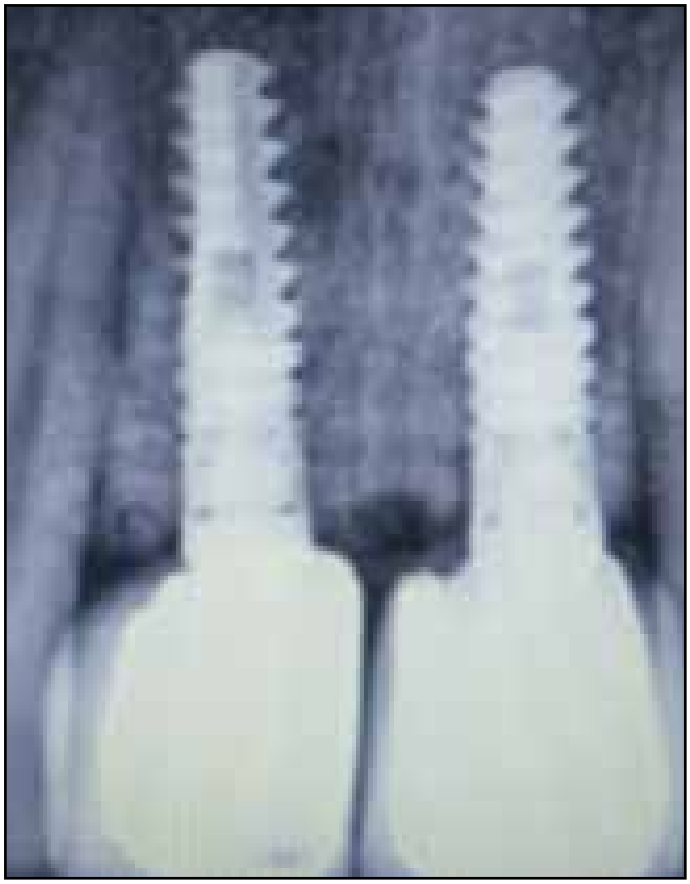

Figure 5b: Radiograph after one year showing no bone loss around implants.

body reaction and also ensures fast healing. However, it is difficult to obtain a sufficient amount and secondary defect develops in the donor site.[7] On the other hand xenograft is not popular because of immune rejection response and high cost.[8] Kim et al.[9] introduced a bone graft material using extracted auto tooth as a new bone graft material to overcome the disadvantages of other grafts.

Auto tooth bone graft materials are of block and granular types. The block type has osteoinduction capacity via blood wettability and has osteoconduction capacity via space maintaining and creeping substitution. It is remodeled by maintaining space during a specific period. The granular type is available in various sizes of particles, porosity between powders.[10]

An immediate implant placement was planned in our cases to reduce the time and cost of therapy and surgical episodes and to preserve the bone and gingival tissues. The greatest rate of bone resorption occurs during the first six months following tooth extraction unless an implant is placed or a socket augmentation procedure performed. The early maintenance of gingival form greatly facilitates the peri-implant gingival tissue esthetics by

Figure 6a: Porcelain fused to metal crowns in situ.

Figure 6b: Porcelain fused to metal crowns in situ.

maintaining support for the interdental papillae.

Currently, all extracted teeth are considered a clinical waste and therefore are simply discarded.[10] The above explained procedure recycles the freshly extracted teeth into a bacteria free particulate autogenous mineralized dentin for immediate grafting with the help of Smart Dentin Grinder. Ike and Urist[11] described that particulate dentinal graft obtained from extracted teeth is used as a carrier of rhBMP-2 because it induces new bone formation in the periodontium. The demineralized treatment of bone and dentin decreased their antigenicity.[12] They possess the ability to coagulate platelet free heparinized, citrated and oxygenated plasmas.[13,14] The extracted non-functional or periodontally involved teeth should not be discarded anymore. Extracted teeth can become an autogenous dentin ready to be grafted within 15 minutes after extraction. Autogenous dentin is the gold standard graft for socket preservation, bone augmentation in sinuses or filling bone defects.

CONCLUSION

There are various bone graft materials available in the market today. In particular, auto tooth bone graft material has been studied aggressively as a material to overcome the disadvantages of allograft, xenograft and synthetic graft without losing bone regeneration capacity like autogenous bone. In clinical applications, auto tooth bone graft material does not have genetic and infectious risks, provides good bone generation through osteoinduction and osteoconduction as well as excellent initial bone remodeling capacity.

Correspondence:
Lt Col Kamal Verma
E-mail:- kamalverma_in@yahoo.com

Disclosure:
The author reports no conflicts of interest with anything in this article.

References

1. Murata M. Autogenous demineralized dentin matrix for maxillary sinus augmentation in human. The first clinical report. 81th Int Assoc Dent Research,Sweden 2003.
2. Finkelman, RD, Mohan S, Jennings JC, Taylor AK, Jepsen S, Baylink DJ. Quantitation of growth factors IGF-I, SGF/IGF-II, and TGF-beta in human dentin. J Bone Miner Res 1990; 5(7):717-23.
3. Kim YK, Yun PY, Kim SG, Lim SC. Sinus bone graft using combination of autogenous bone and BioOss(R): comparison of healing according to the ratio of autogenous bone. J Korean Assoc Oral Maxillofac Surg 2007;33:6549.
4. Reddi AH. Bone matrix in the solid state: geometric influence on differentiation of fibroblasts. Adv Biol Med Phys 1974;15: 1-18.
5. Kim YK et al. Development of a novel bone grafting material using autogenous teeth. Oral Surg Oral Med Oral Pathol Oral Radiol Endod 2010;109:496503.
6. Huggins C, Wiseman S, Reddi AH. Transformation of fibroblasts by allogeneic and xenogeneic transplants of demineralized tooth and bone. J Exp Med1970;132: 1250-1258.
7. Morotome Y, Gosekisone M, Ishikawa I, Oida S. Gene expression of growth and differentiation factors-5,6 and7 in developing bovine tooth at the root forming stage. Biochem Biophys Res Commun 1988; 244(1): 85-90.
8. Park SM et al Clinical application of auto tooth bone graft material. J Korean Assoc Oral Maxillofac Surg 2012;38:2-8.
9. Kim YK et al. Bone graft material using teeth. J Korean Assoc Oral Maxillofac Surg 2012;38:134-8.
10. Binderman I, Hallel G, Nardy C, Yaffe A, Sapoznikov L. A Novel Procedure to Process Extracted Teeth for Immediate Grafting of Autogenous Dentin. J Interdiscipl Med Dent Sci 2014;2(6):154-159.
11. Ike M, Urist MR. Recycled dentin root matrix for a carrier of recombinant human bone morphogenic protein. J Oral Implantol 1998;24:124-32.
12. Yeomans, JD. & Urist, MR. Bone induction by decalcified dentine implanted into oral, osseous and muscle tissues. Arch Oral Biol 1967;12:999-1008.
13. Qin C, Brunn JC, Cadena E, Ridall A, Tsujigiwa H. The expression of dentin sialophosphoprotein gene in bone. J Dent Res 2002;81: 392-394.
14. Schmidt TH, Schultz M. Intact growth factors are conserved in the extracellular matrix of ancient human bone and teeth: a storehouse for the study of human evolution in health and disease. Biol Chem 2005; 386: 767-776.
15. Schwarz F, Golubovic V, Mithatovic I, Becker J. Periodontally diseased tooth roots used for lateral alveolar ridge augmentation. J Clin Periodontol 2016;43:797-803.
16. Saebe M. Mini review: Dentin as bone graft substitution. Songklanakarin Dent J 2014;2(1): 21-27.

JIACD
The Journal of Implant & Advanced Clinical Dentistry

ATTENTION PROSPECTIVE AUTHORS

JIACD wants to publish your article!

For complete details regarding publication in JIACD, please refer to our author guidelines at the following link:
jiacd.com/author-guidelines
or email us at:
editors@jicad.com

JIACD OsseoFuse International Inc.

The Journal of Implant and Advanced Clinical Dentistry has been providing high quality, peer reviewed dental journals since 2007. We take pride in knowing that tens of thousands of readers around the world continue to read and contribute articles to JIACD. As you can imagine, there is a lot of expense involved in managing a top quality dental journal and we sincerely appreciate our advertisers purchasing ad space in both the journal and on the website which allows our monthly journals to continue to be free to all of our readers.

In an effort to streamline our business practice and continue to provide no-fee, open access journals, JIACD is now sponsored exclusively by Osseofuse International Inc., a cutting edge dental implant company that provides exceptional implants and prosthetics and believes in the free distribution of information towards clinical advancements to dentists in the U.S. and around the world.

This generous sponsorship, which provides funding towards our operating expenses, allows JIACD to focus on the more important aspects of our journal; monthly publishing of relevant clinical practices.

As a reader or author of JIACD, nothing will change. In fact, readers will see less advertisements overall and authors can continue to submit articles relating to any clinical topic.

We here at JIACD sincerely appreciate the continued financial support by Osseofuse International Inc., and are excited about the opportunity it affords. Thank you once again for your generous support.

Sincerely,

Leon Chen MD, MS, Co-Editor-in-Chief | Dave Beller, Director |The JIACD Team

Thank you